

# The Gastrointestinal Tract

---

Pete Takizawa

# What we'll talk about...

---

- Structural and functional layers of the GI tract
- Structure and function of gastric glands
- Regulation of acid secretion
- Structure and function of small intestine
- Innervation and movement of chyme

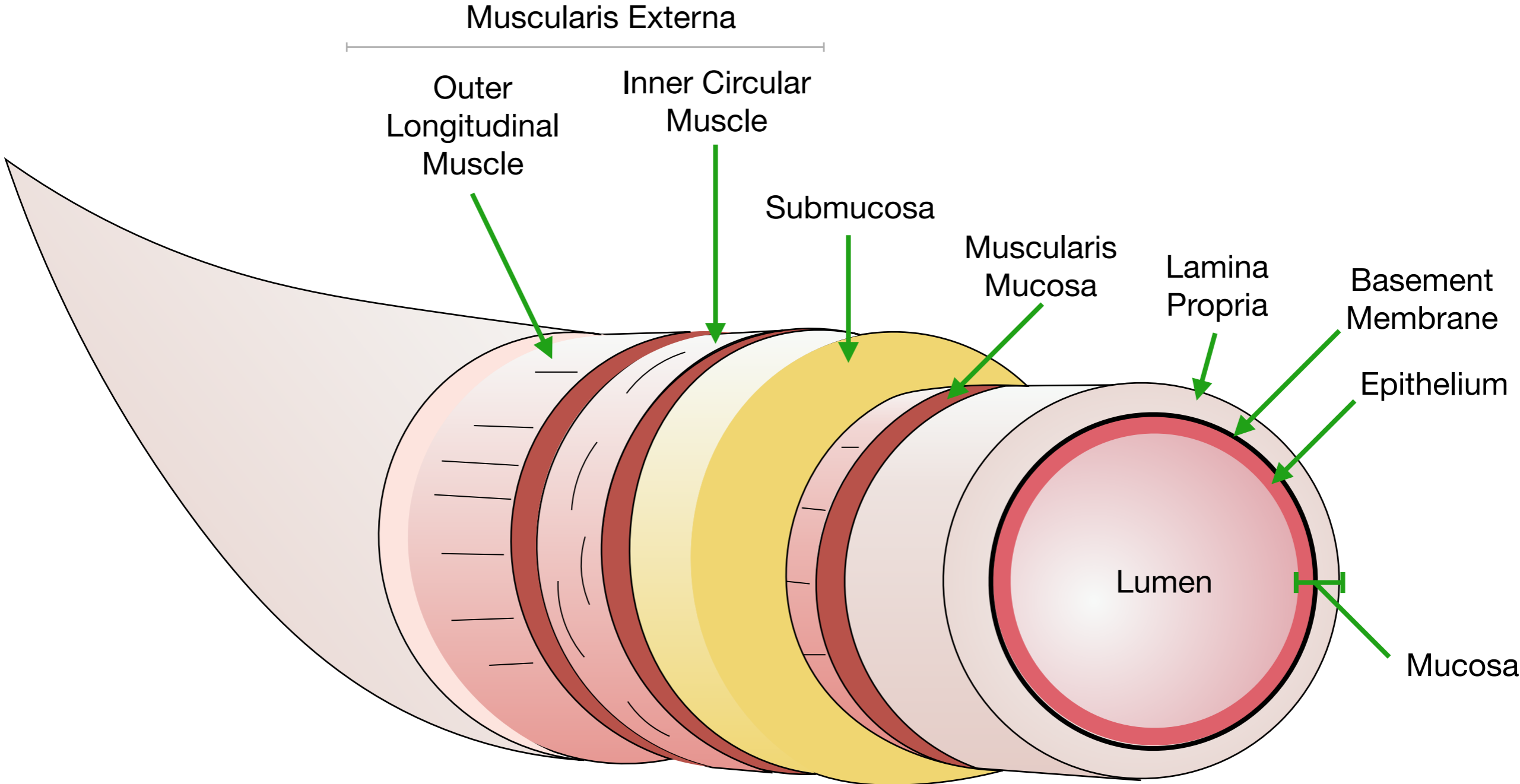
The GI tract is a long tube that digests food, absorbs nutrients and processes waste.

---

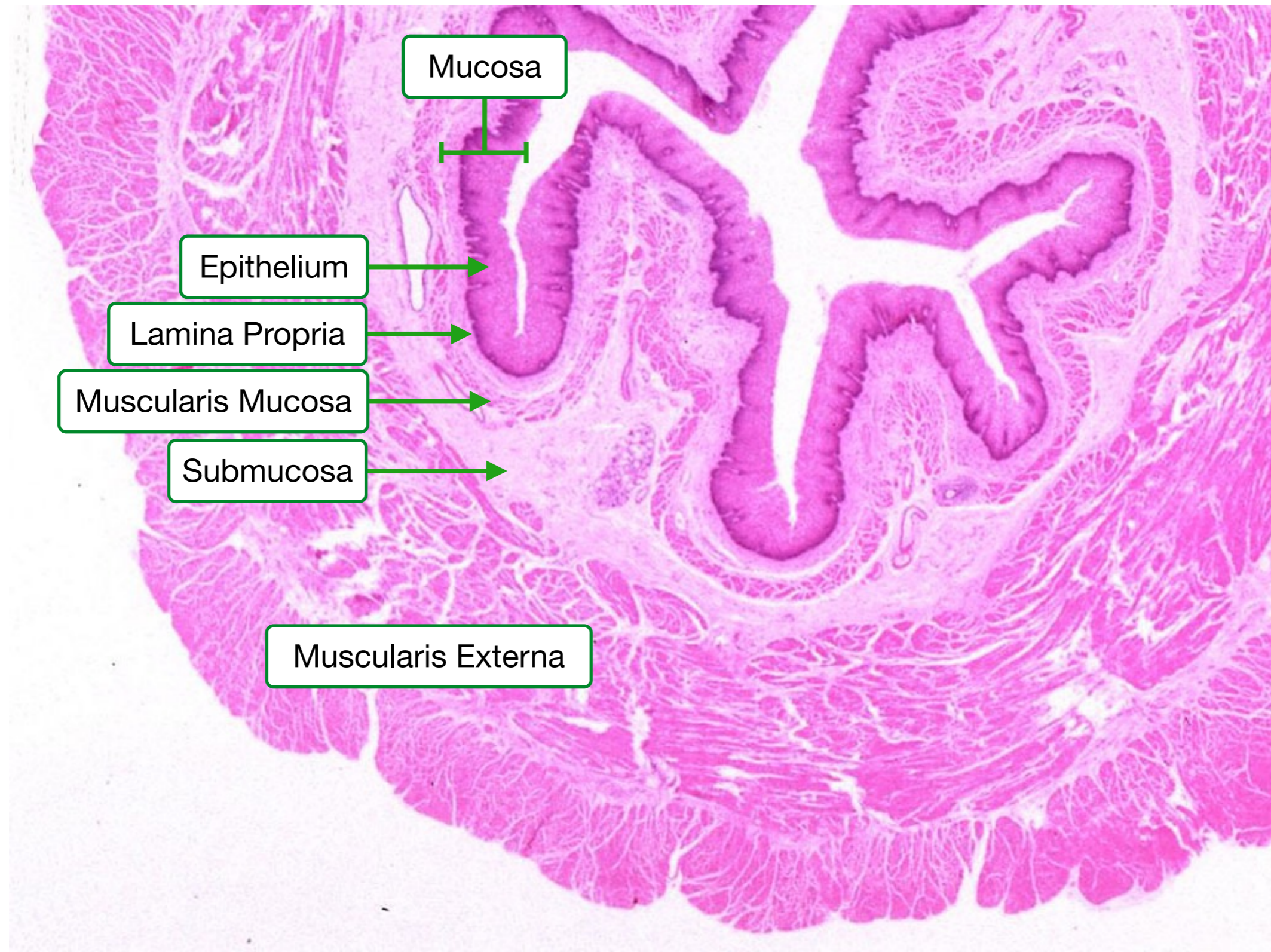
- Stomach
- Small Intestine
- Large Intestine (Colon)

The GI tract is a long tube with multiple distinct functional and structural layers.

---



A cross-section of the esophagus reveals the histological layers of the GI tract.



# The GI tract contains four different type of mucosa.

---

- Protective
- Secretory
- Absorptive - Nutrients
- Absorptive - Water and electrolytes

# Junctions separate segments of the GI tract.

---

- Gastro-esophageal
- Gastro-duodenal
- Ileo-cecal
- Recto-anal

Mucosa surface area is amplified through several different structures.

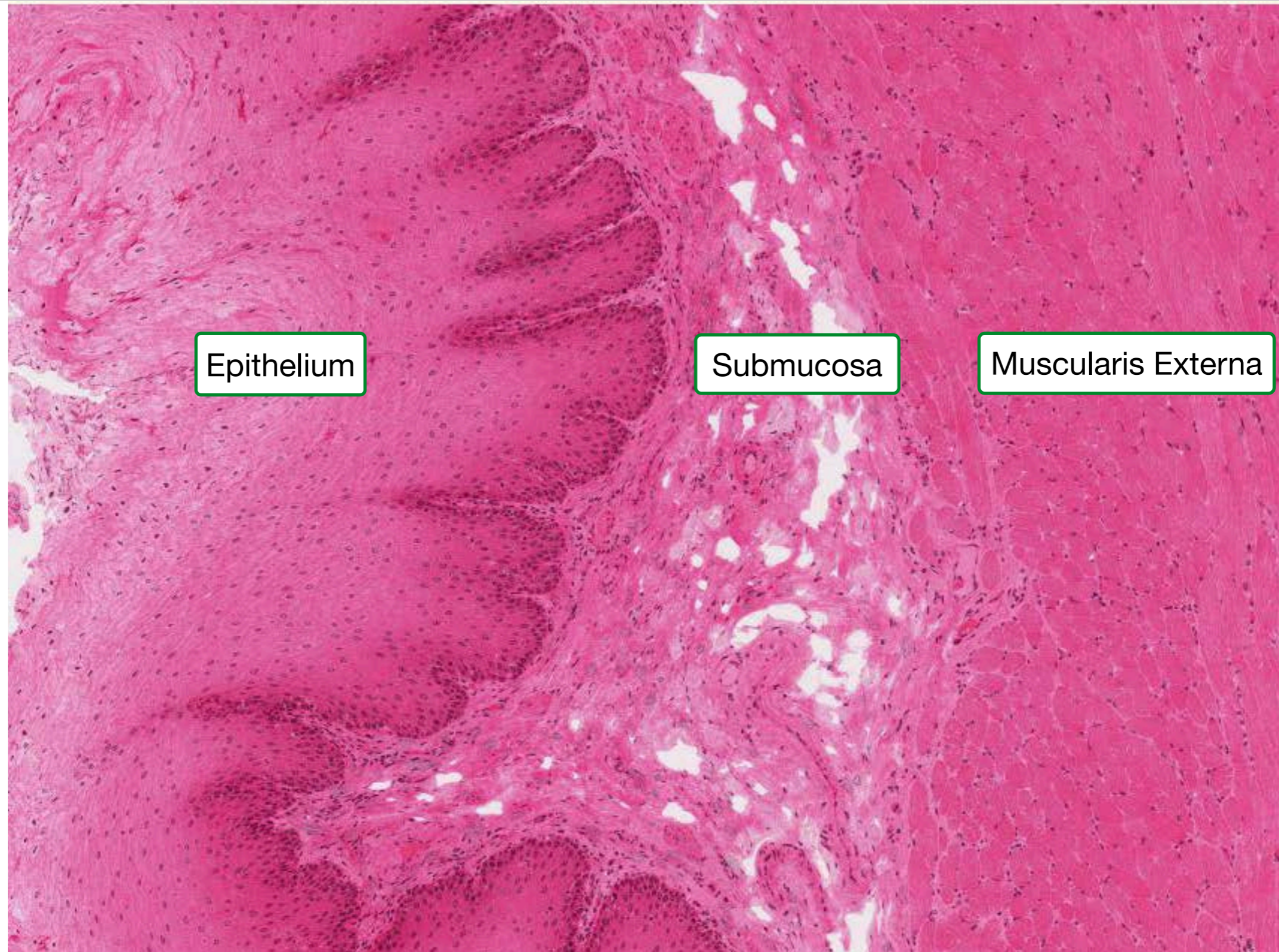
---

- Glands
- Microvilli
- Villi
- Plicae circularis

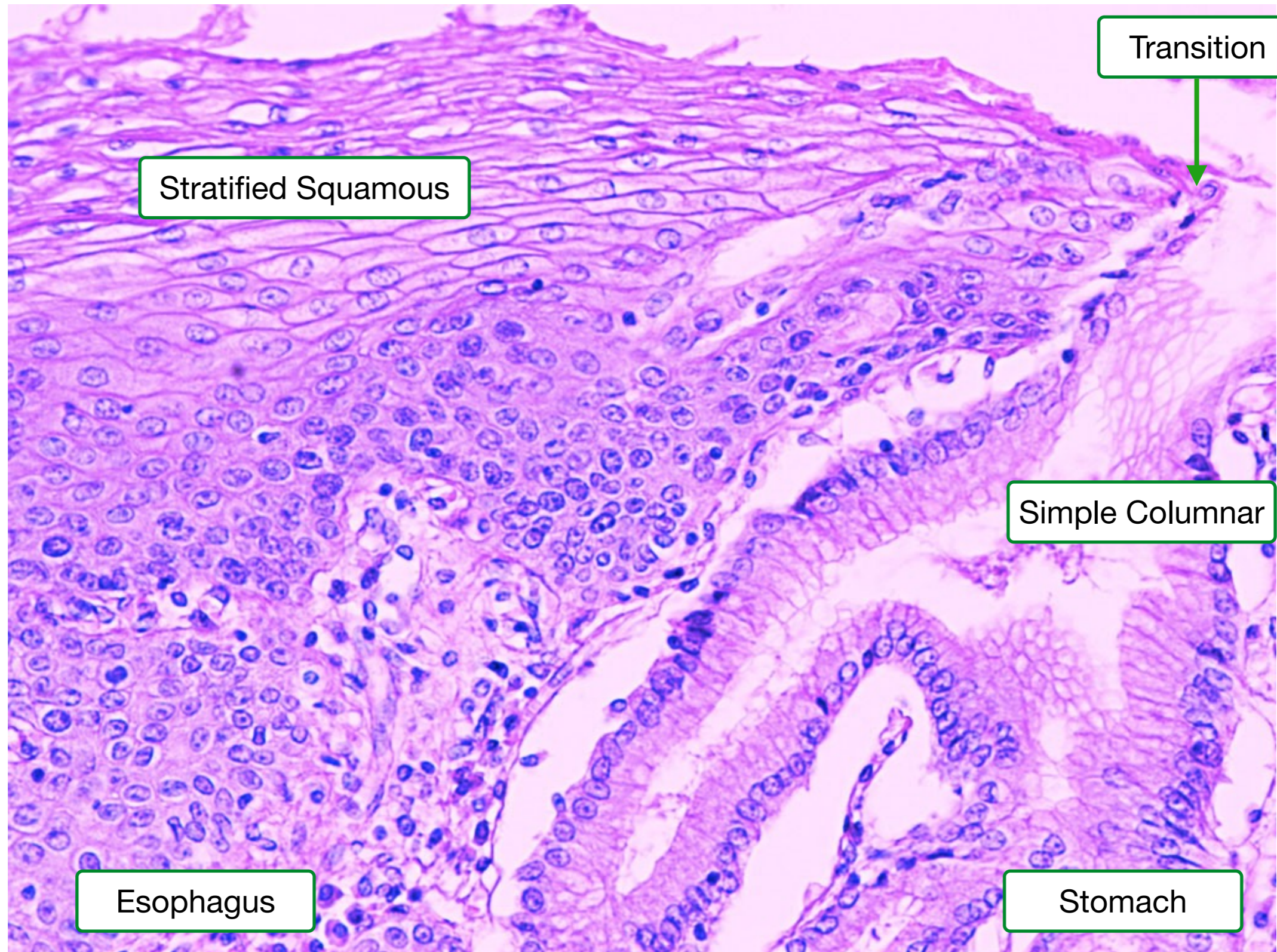


# Segments of the GI Tract

A stratified squamous epithelium lines the esophagus and skeletal muscle surrounds the upper portion.

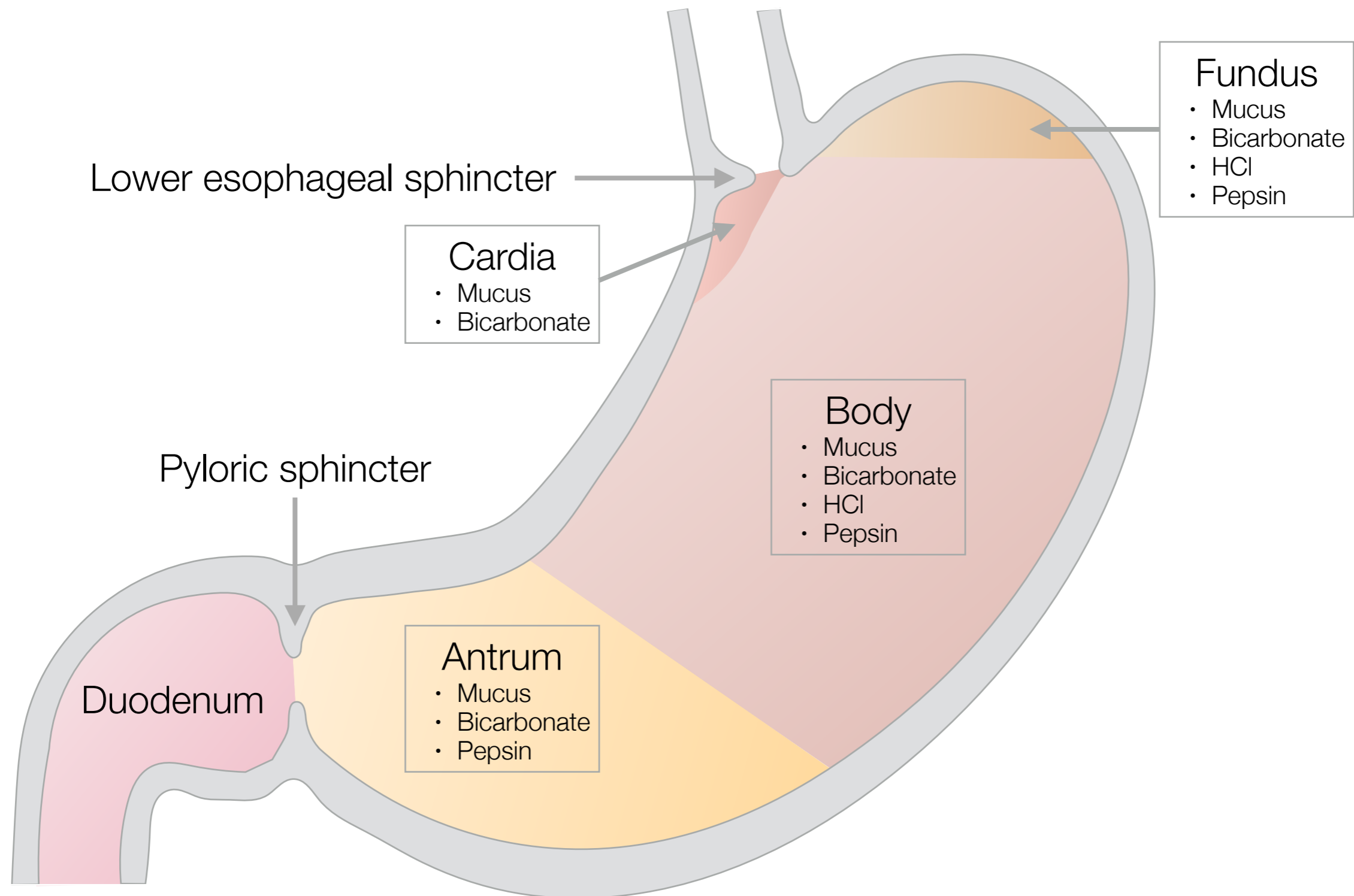


The epithelium transition from stratified squamous to simple columnar at the esophagus-stomach junction.



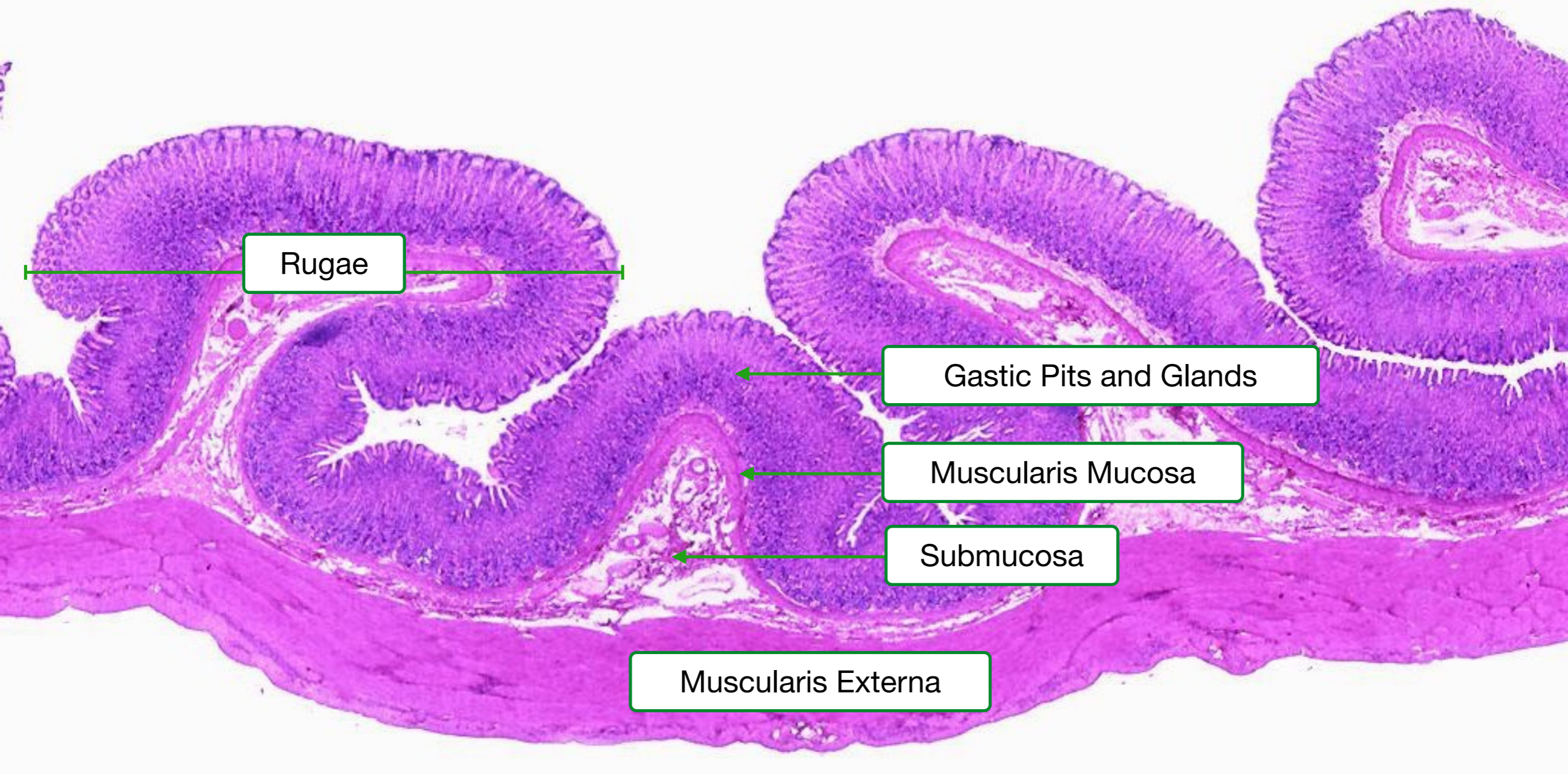
The stomach contains several functionally and structurally distinct domains.

---

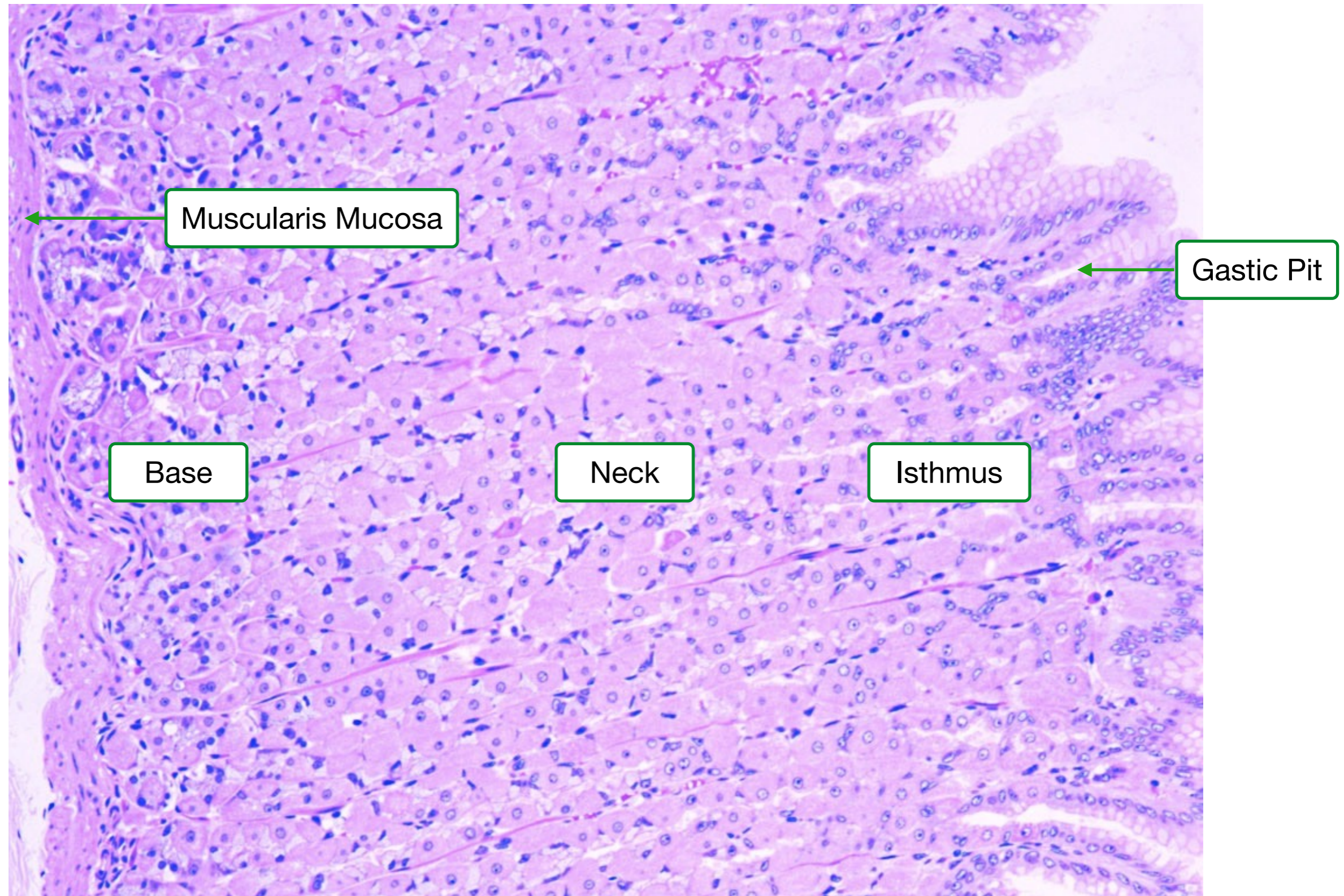


The stomach contains gastric glands arranged into large folds called rugae.

---

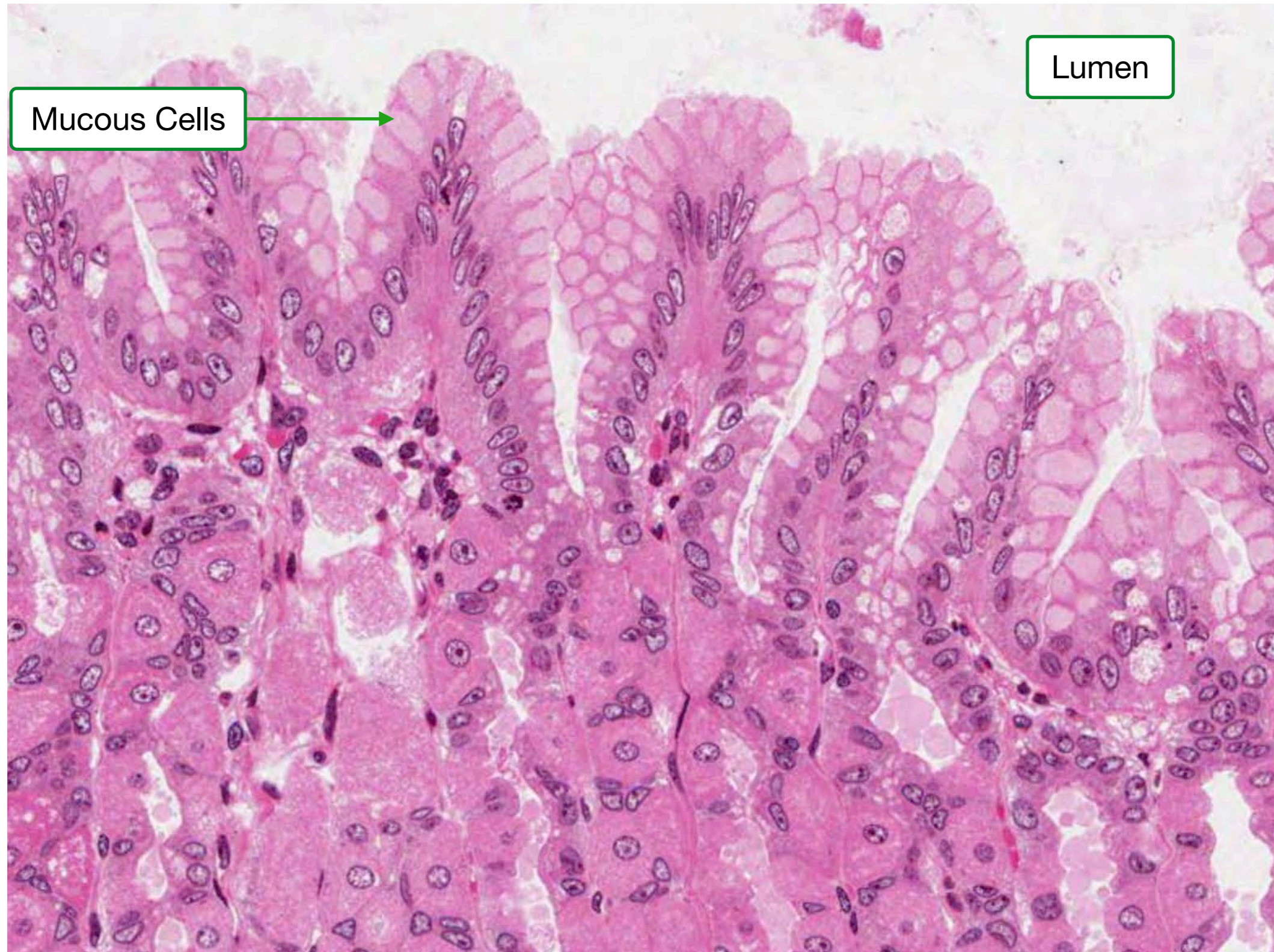

The gastric gland is the main functional unit of the stomach and produces mucus, acid and pepsin.



# Cells of Gastric Glands

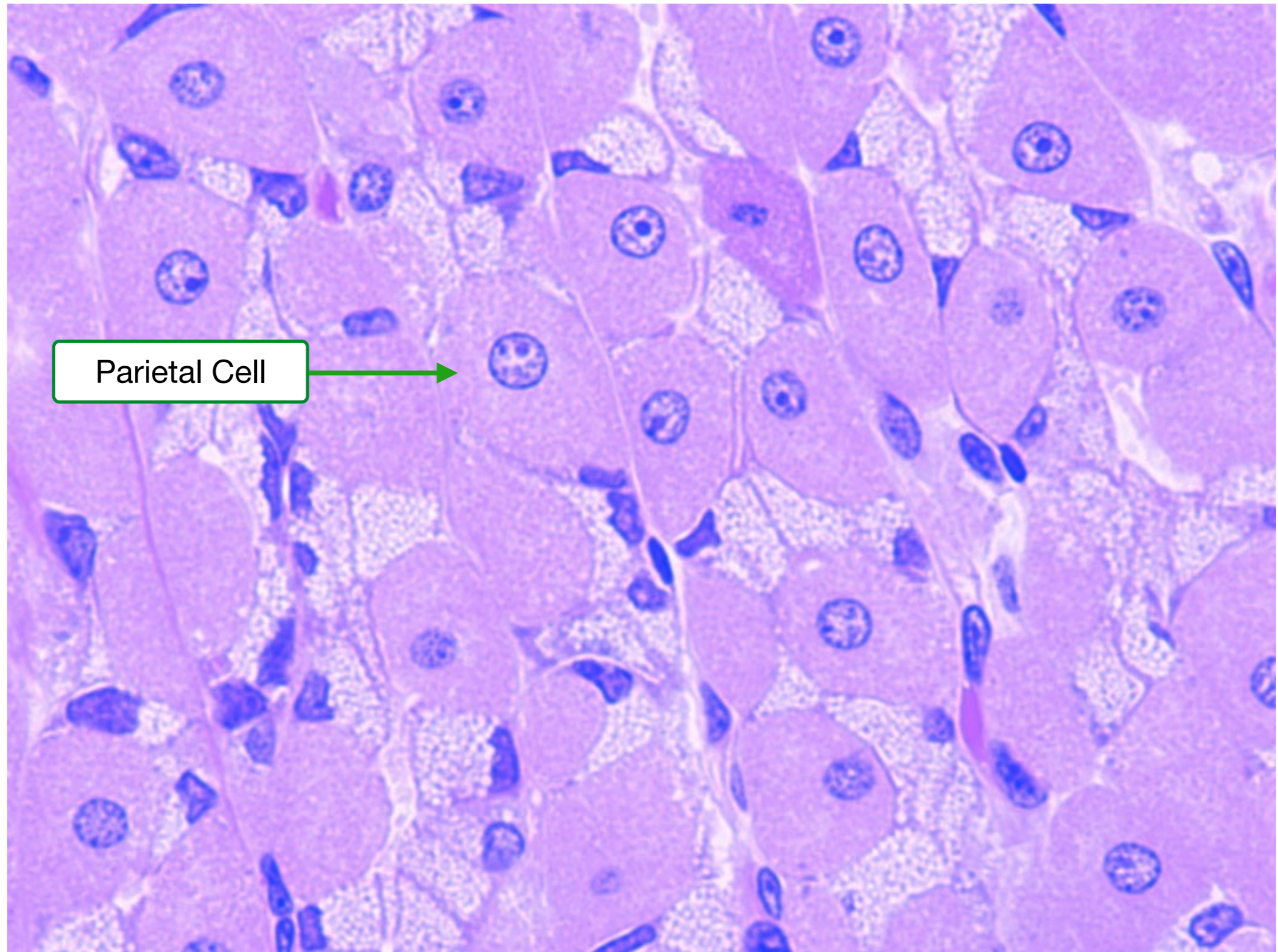
Mucus-secreting cells predominantly reside at the tips of the gastric pits.





Parietal cells reside in the isthmus region and secrete acid.

---



Parietal cells in the stomach epithelium secrete acid via hydrogen ion pumps in their apical membranes.

Lumen

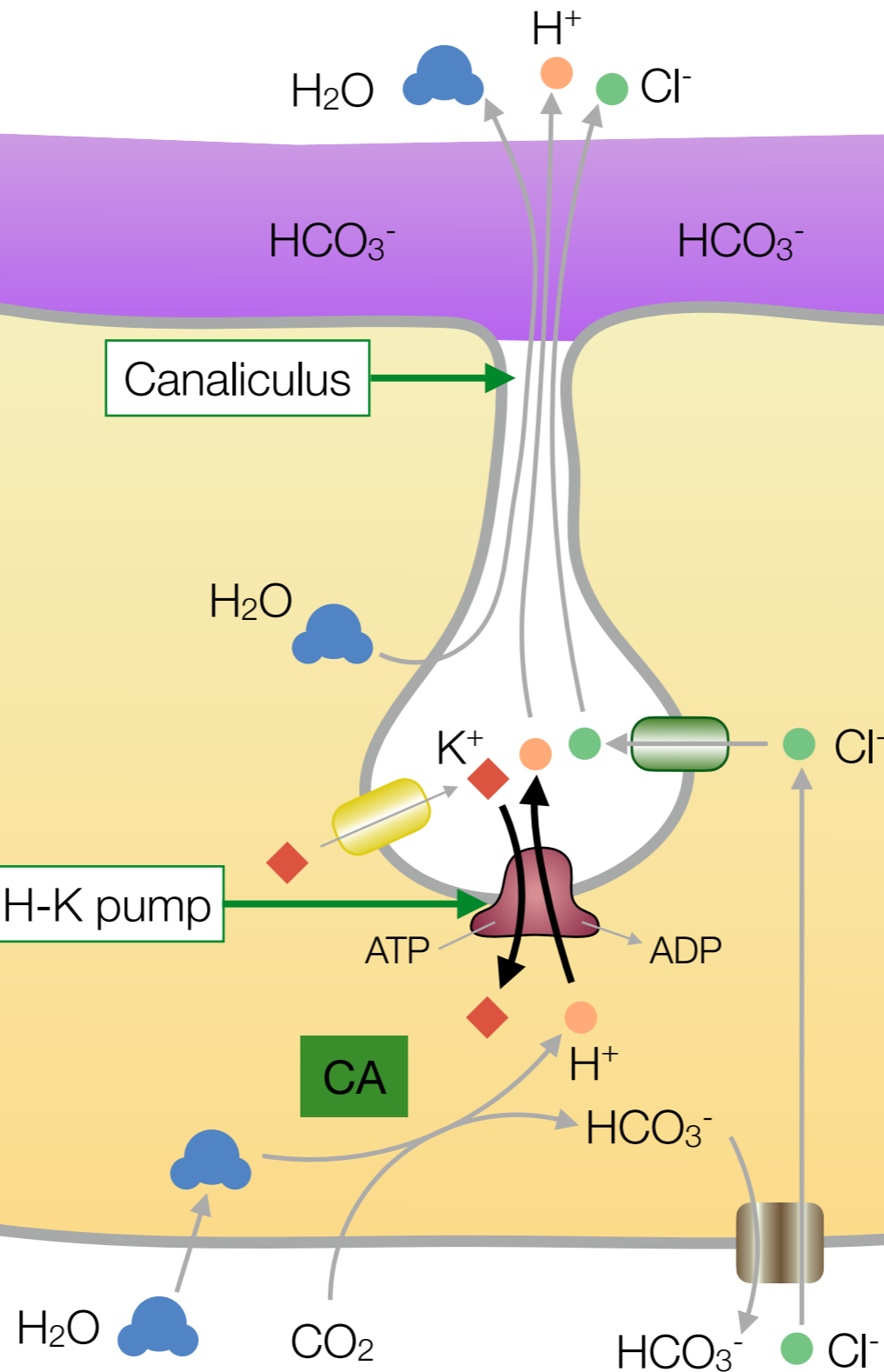
Mucus

Canaliculus

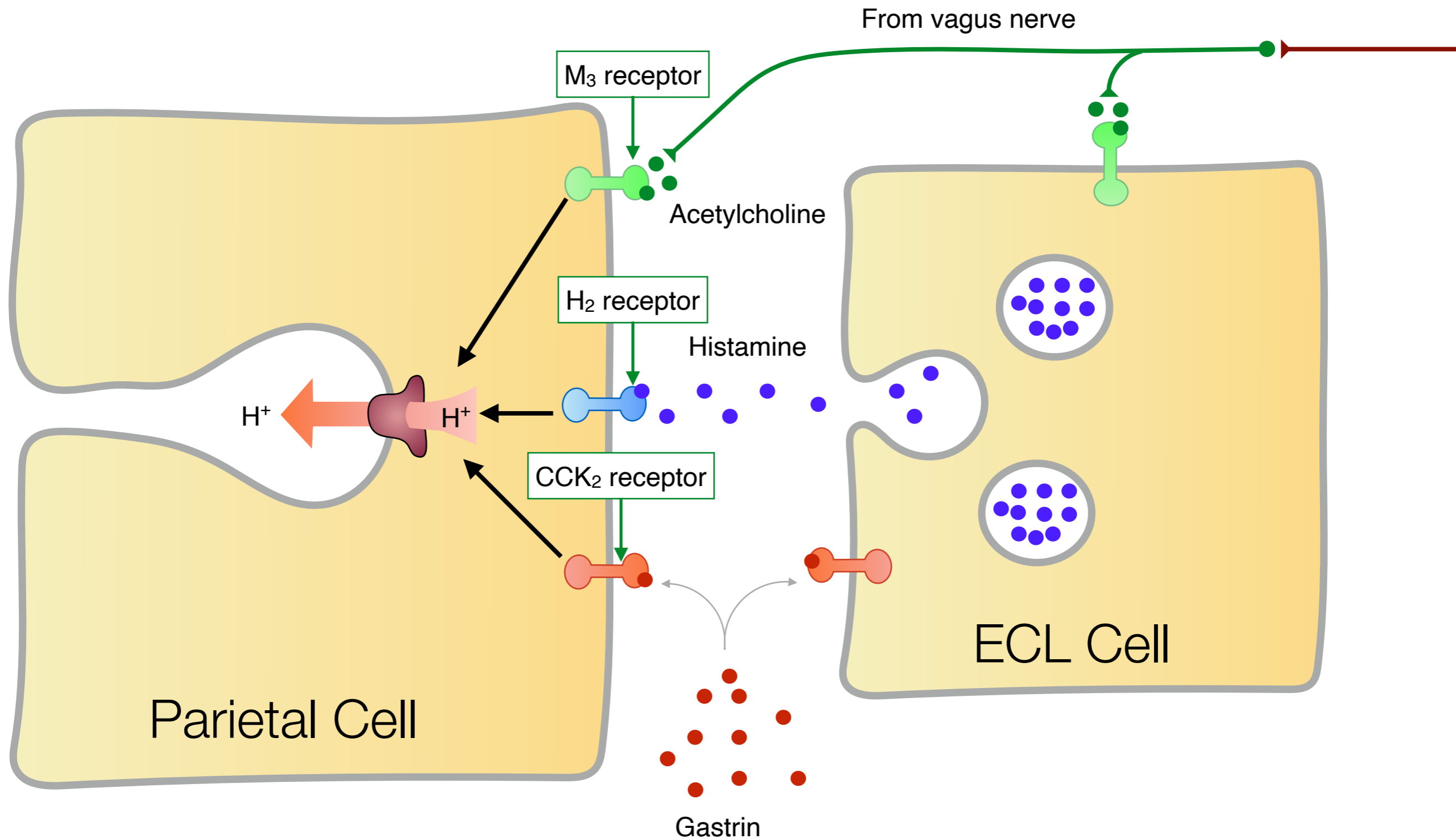
H-K pump

CA

Parietal Cells

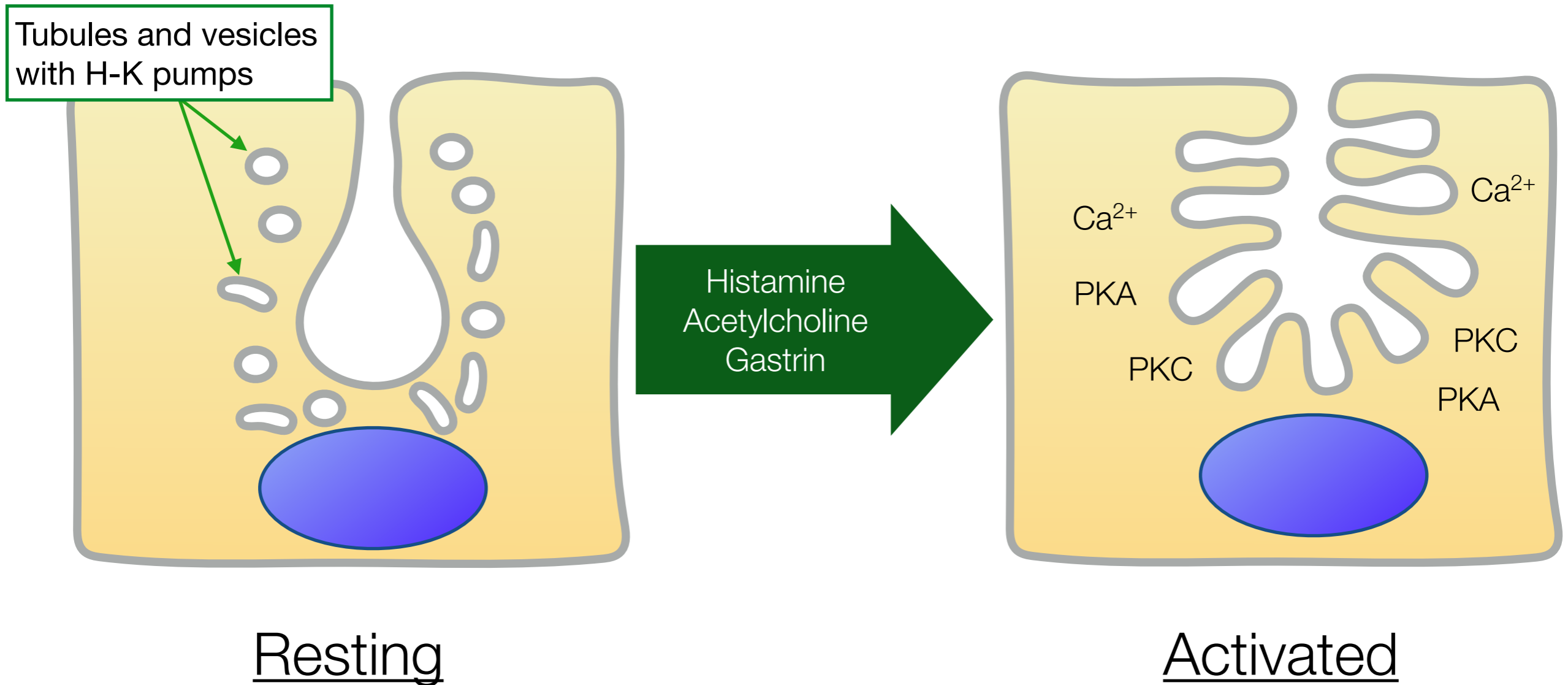


Acetylcholine, histamine and gastrin increase acid secretion by parietal cells.



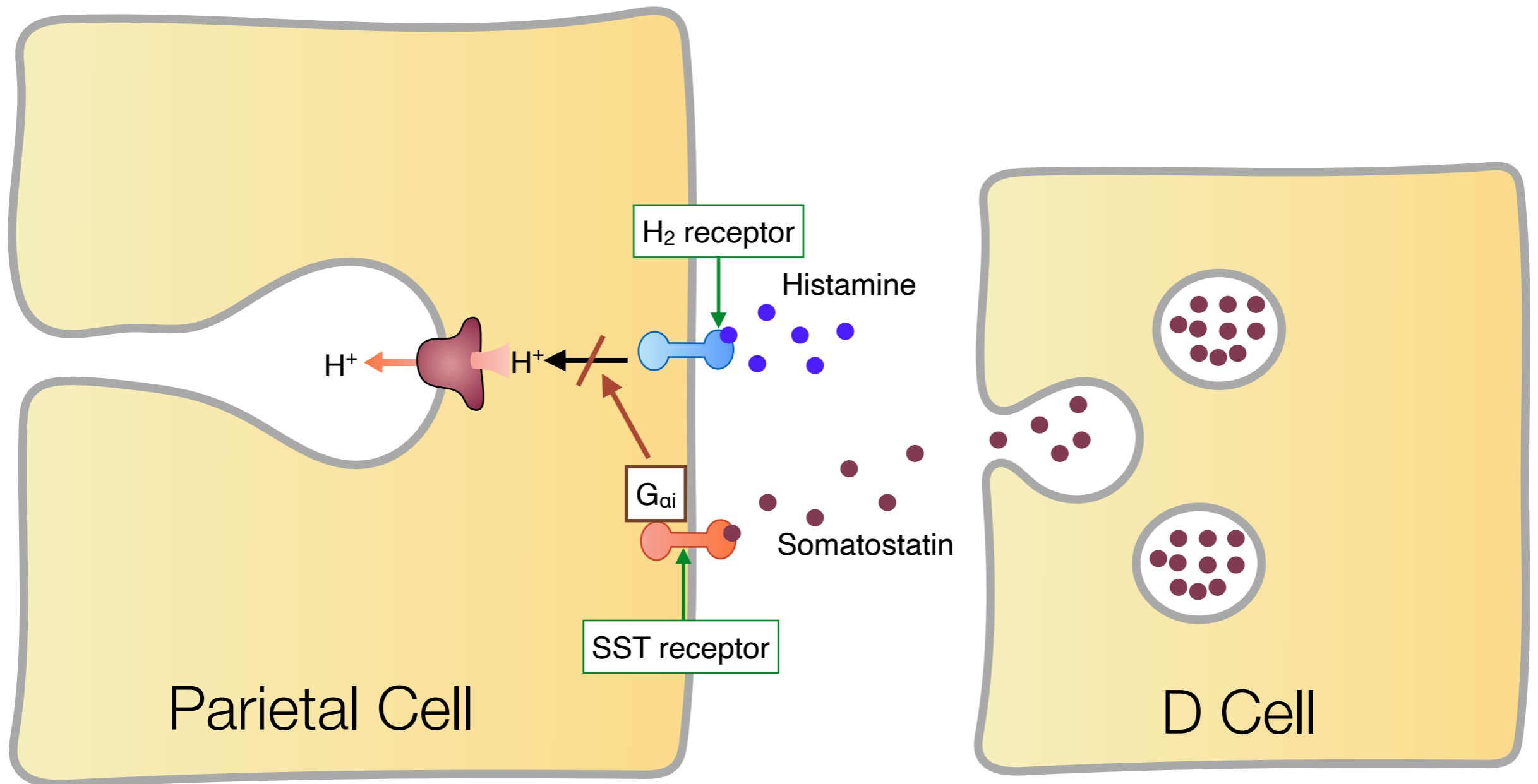
Activation of parietal cells increases their apical surface area through formation of canaliculi.

---

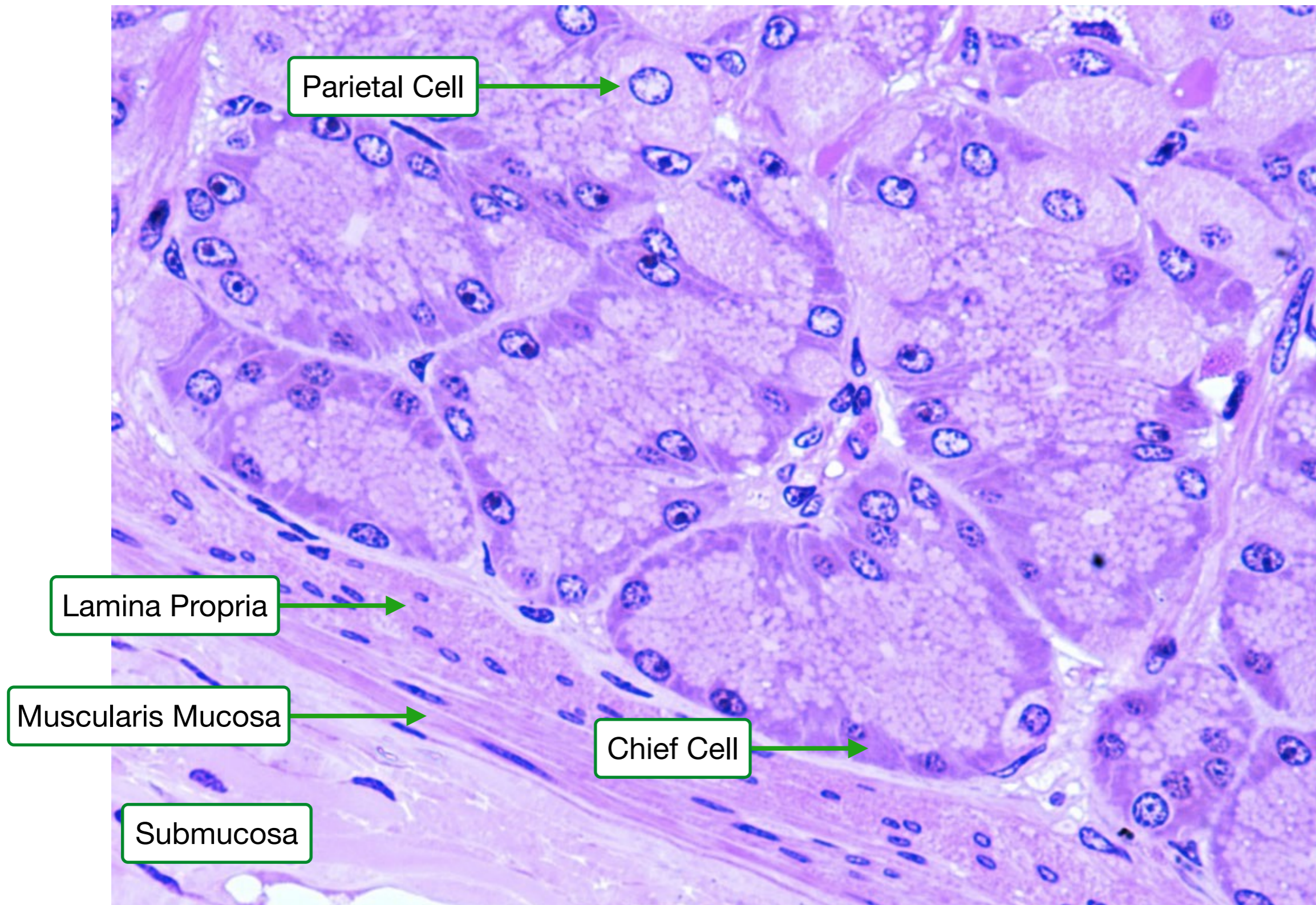


D cells release somatostatin which inhibits acid secretion by parietal cells.

---



Chief cells reside at the base of glands and secrete the pro-enzyme pepsinogen.



Gastric glands contains different endocrine cells that primarily regulate the activity of parietal cells.

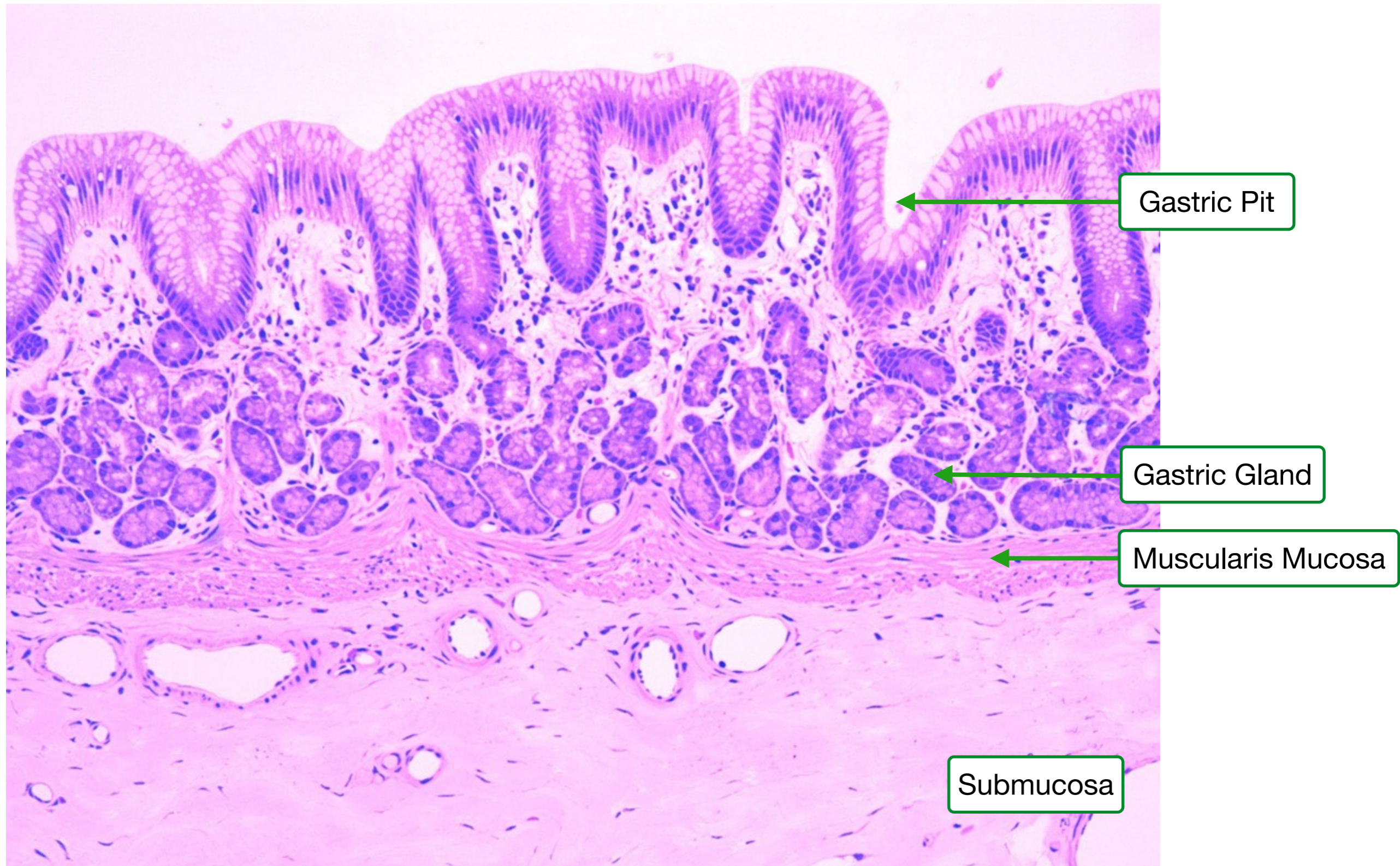---

- Enterochromaffin-like cells (ECL) - produce histamine
- G cells - produce gastrin
- D cells - produce somatostatin

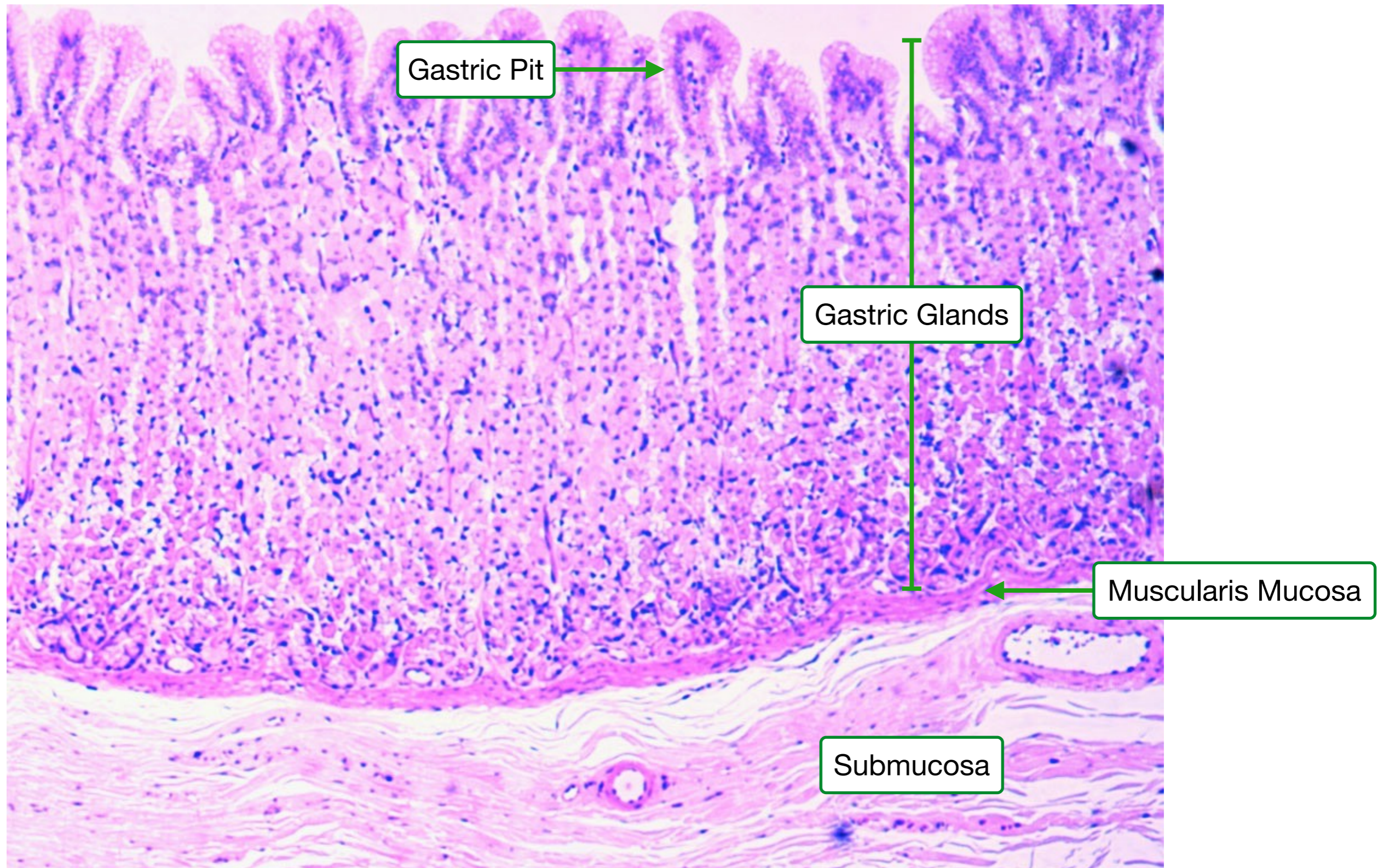
Regions of the stomach



The cardia contains highly convoluted glands that primarily produce mucus.

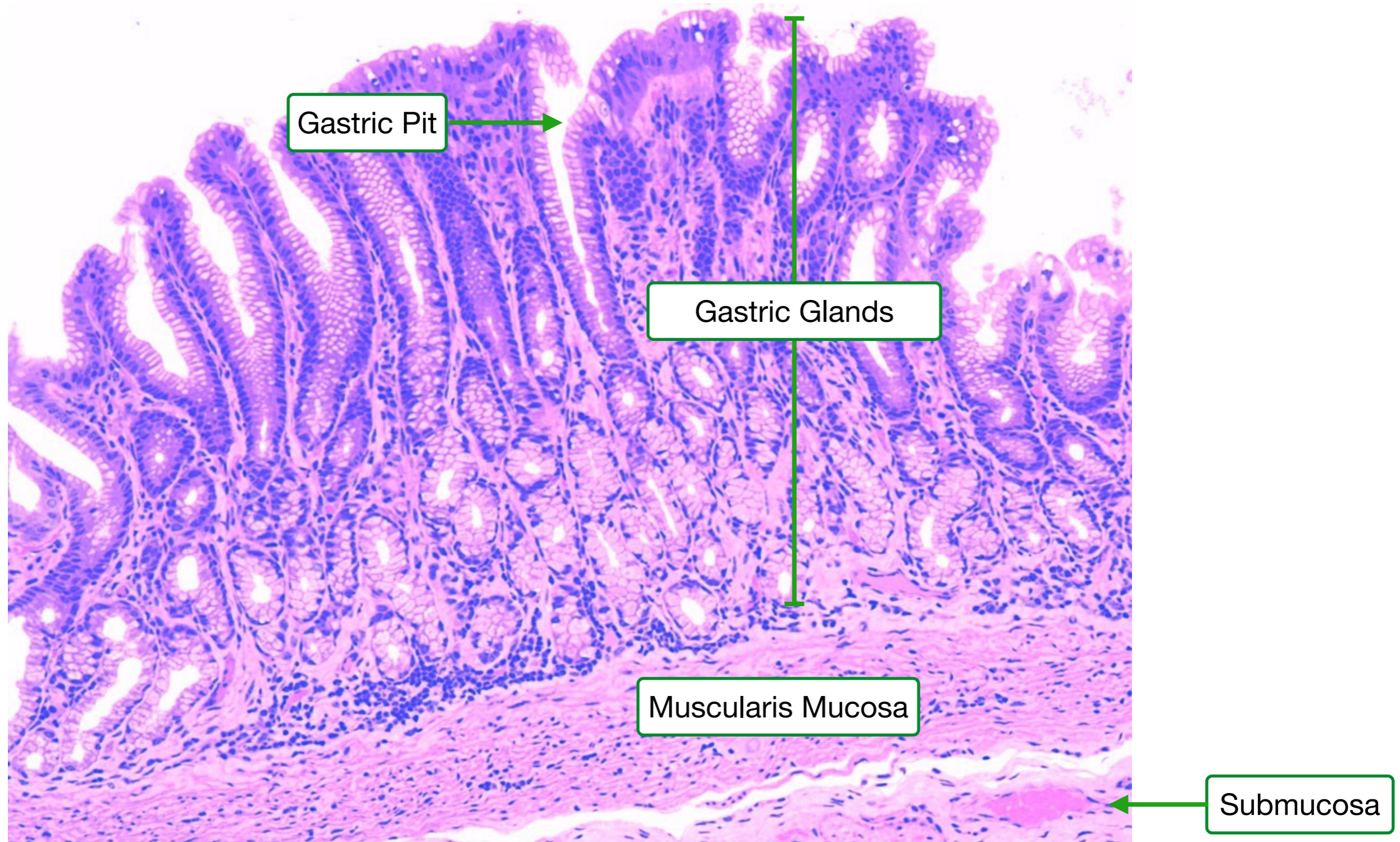


The body contains long, straight glands that produce acid and pepsinogen.



The antrum contains mucus-secreting cells and endocrine cells but lacks parietal cells.

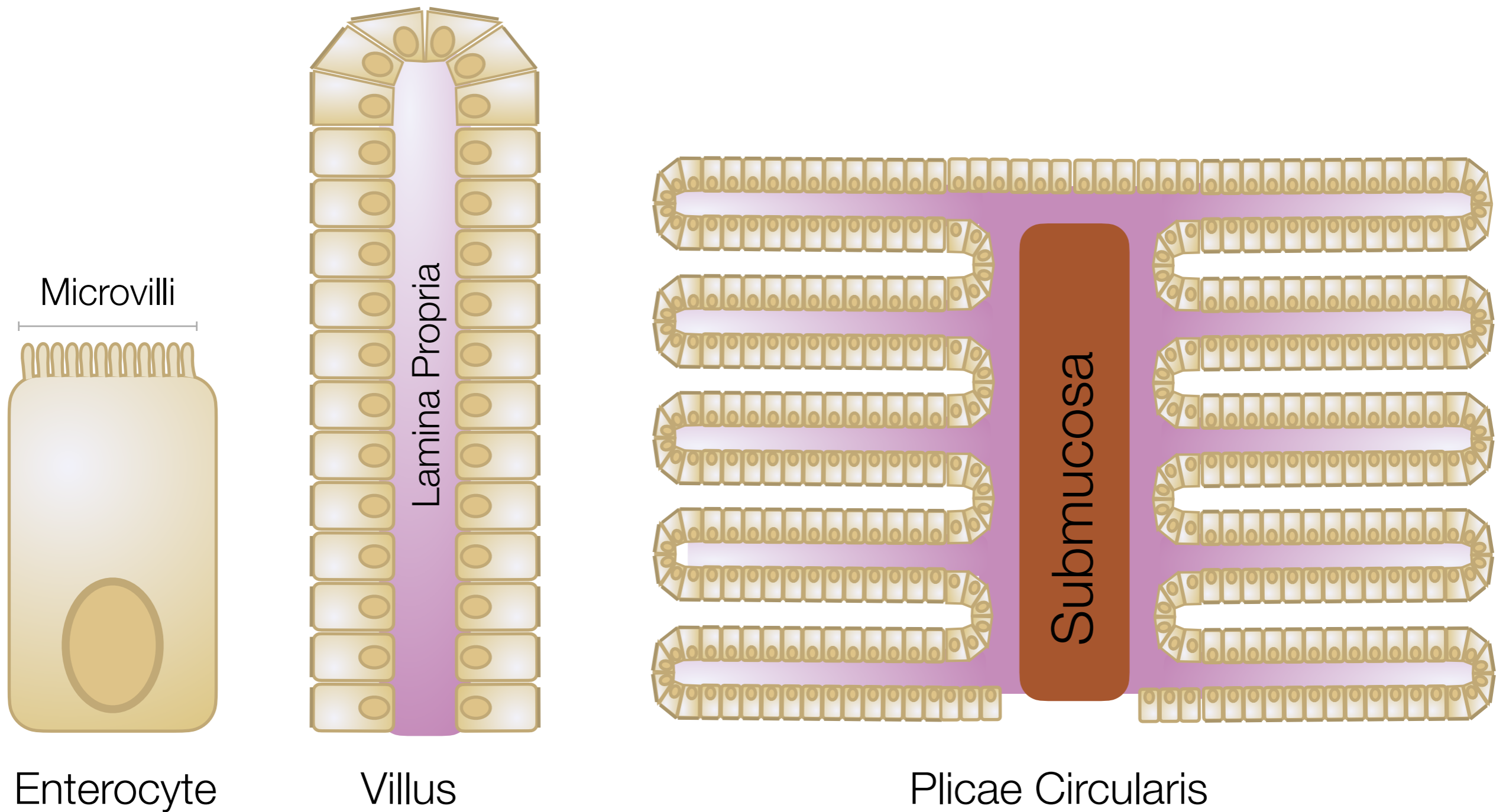
---



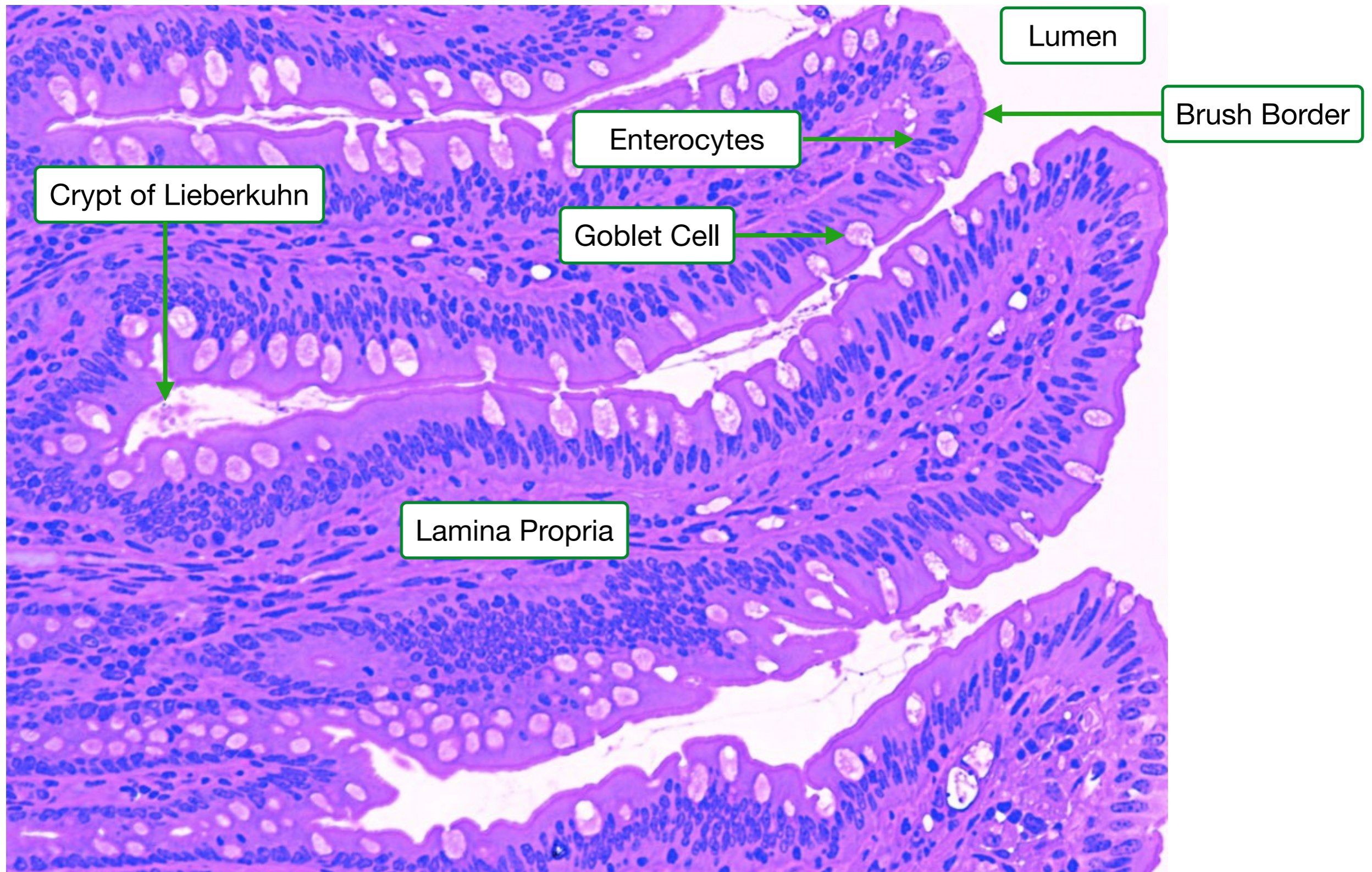
Small Intestine

Microvilli, villi and plicae circulares amplify the surface area of the small intestine.

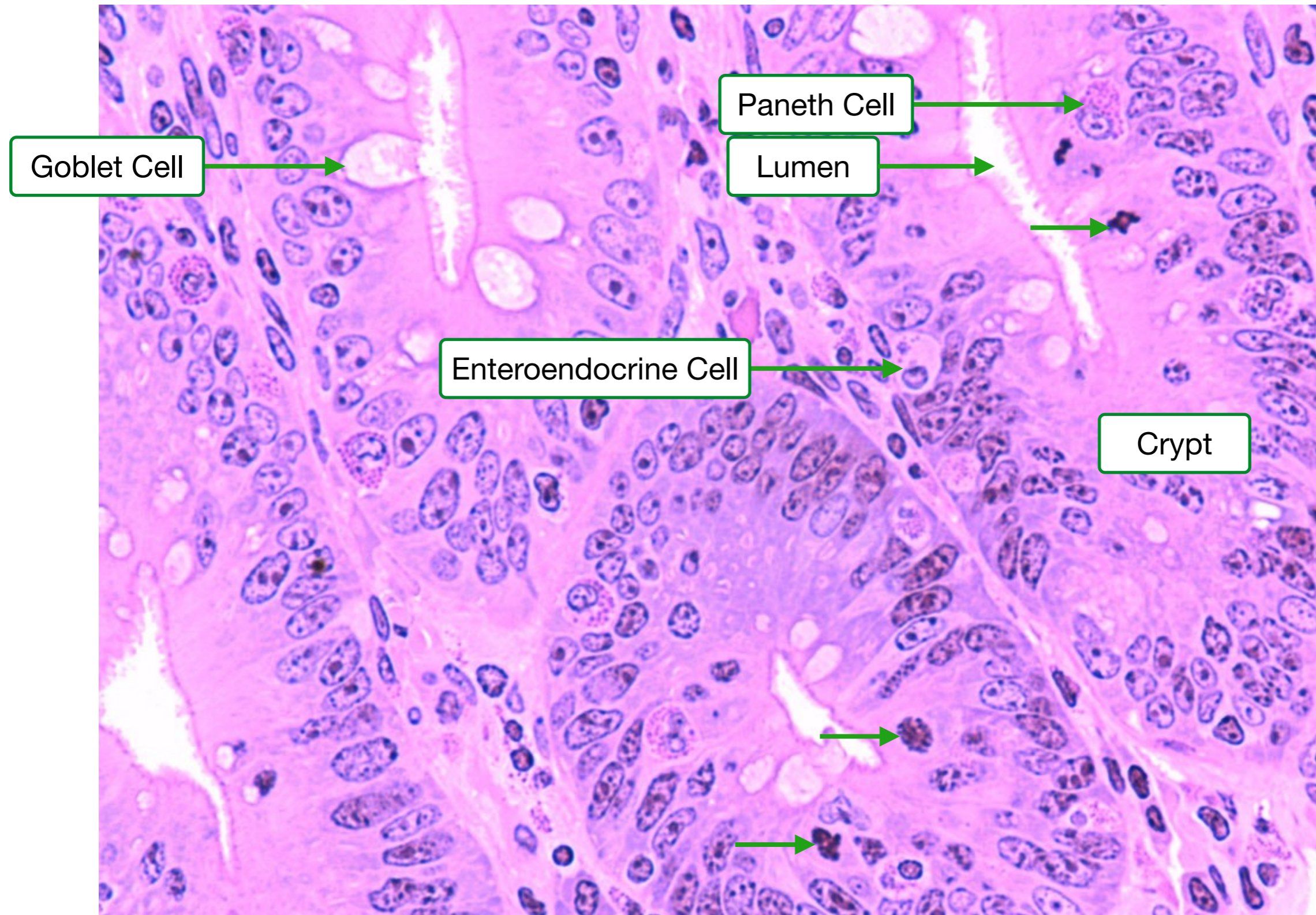
---



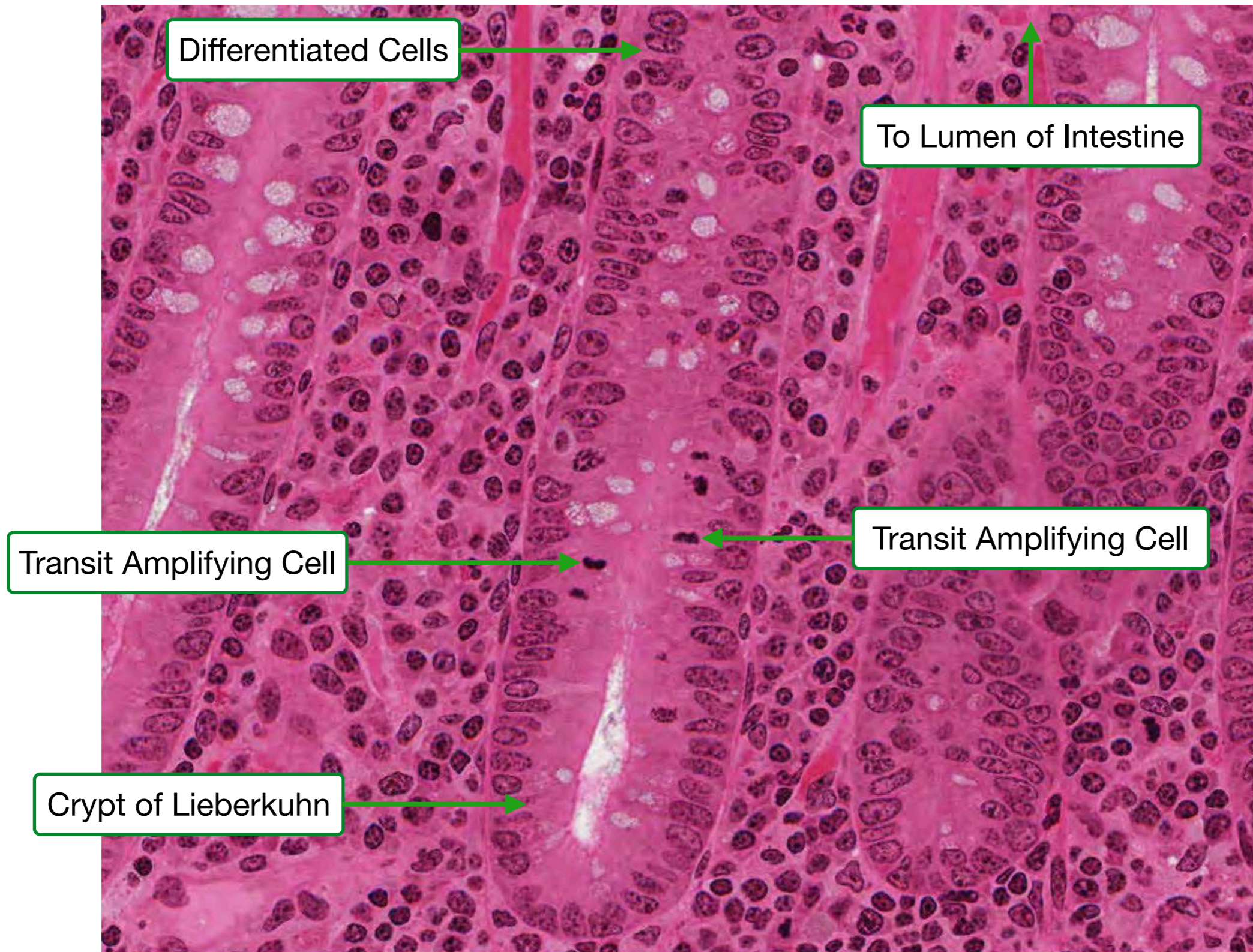
Villi are outfoldings of lamina propria and epithelium that contain mostly enterocytes and goblet cells.



Crypts of Lieberkuhn are the base of villi and contain stem cells, endocrine cells and immune cells.



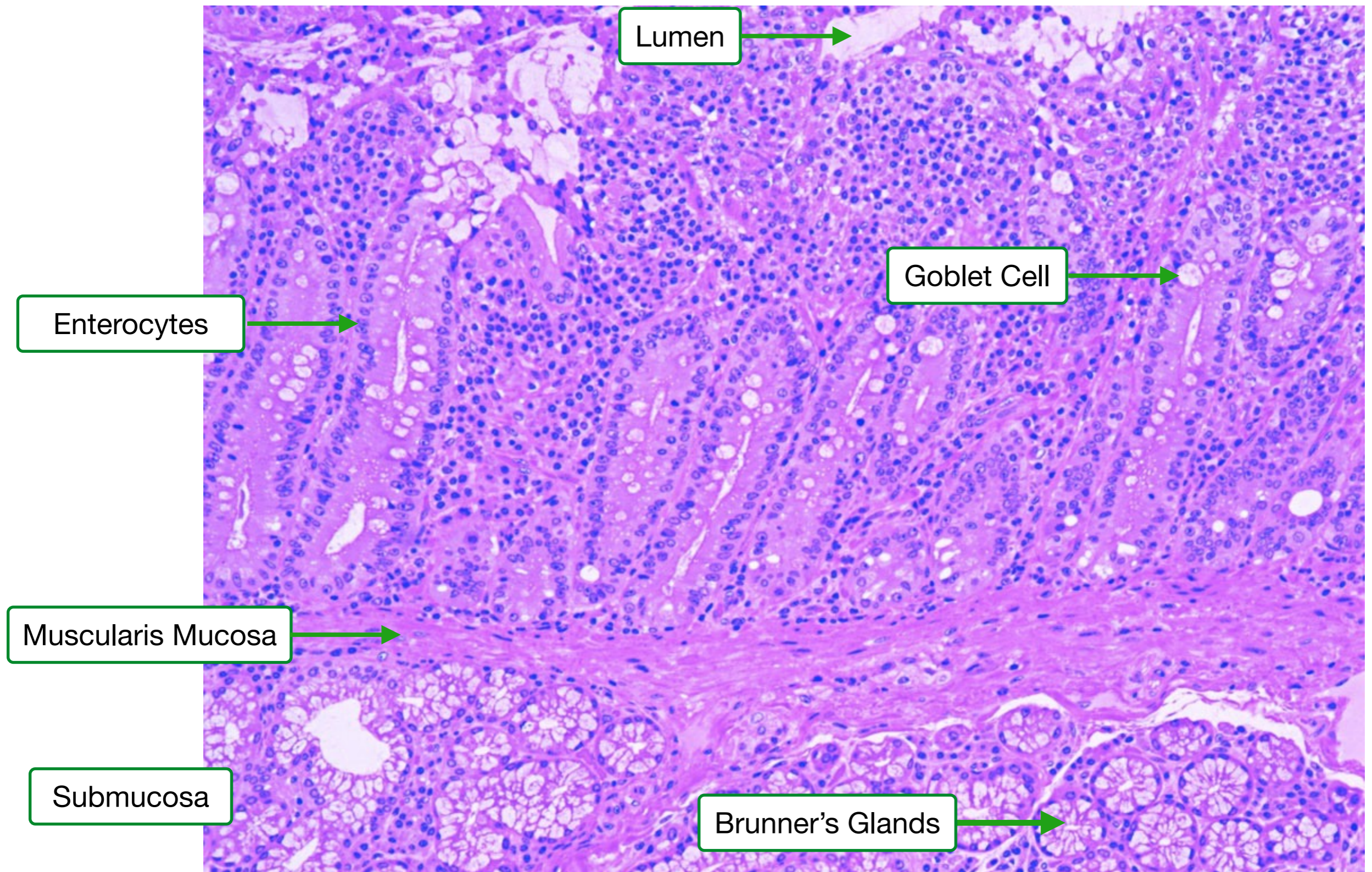
Renewal of intestinal epithelium involves stem cells and transit amplifying cells.





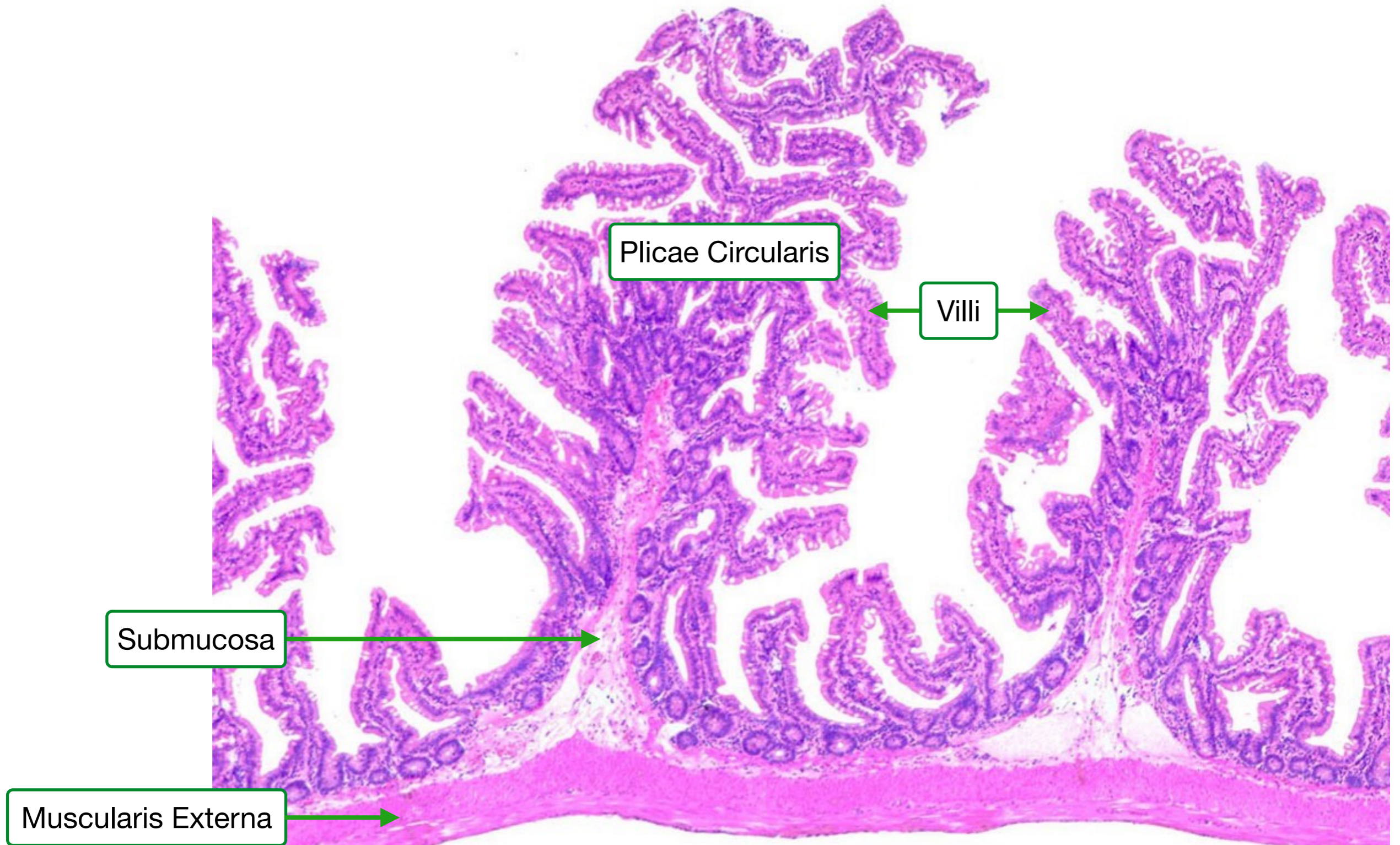
Segment of the small intestine

The duodenum is the initial segment of the small intestine and has Bruner's glands in its submucosa.

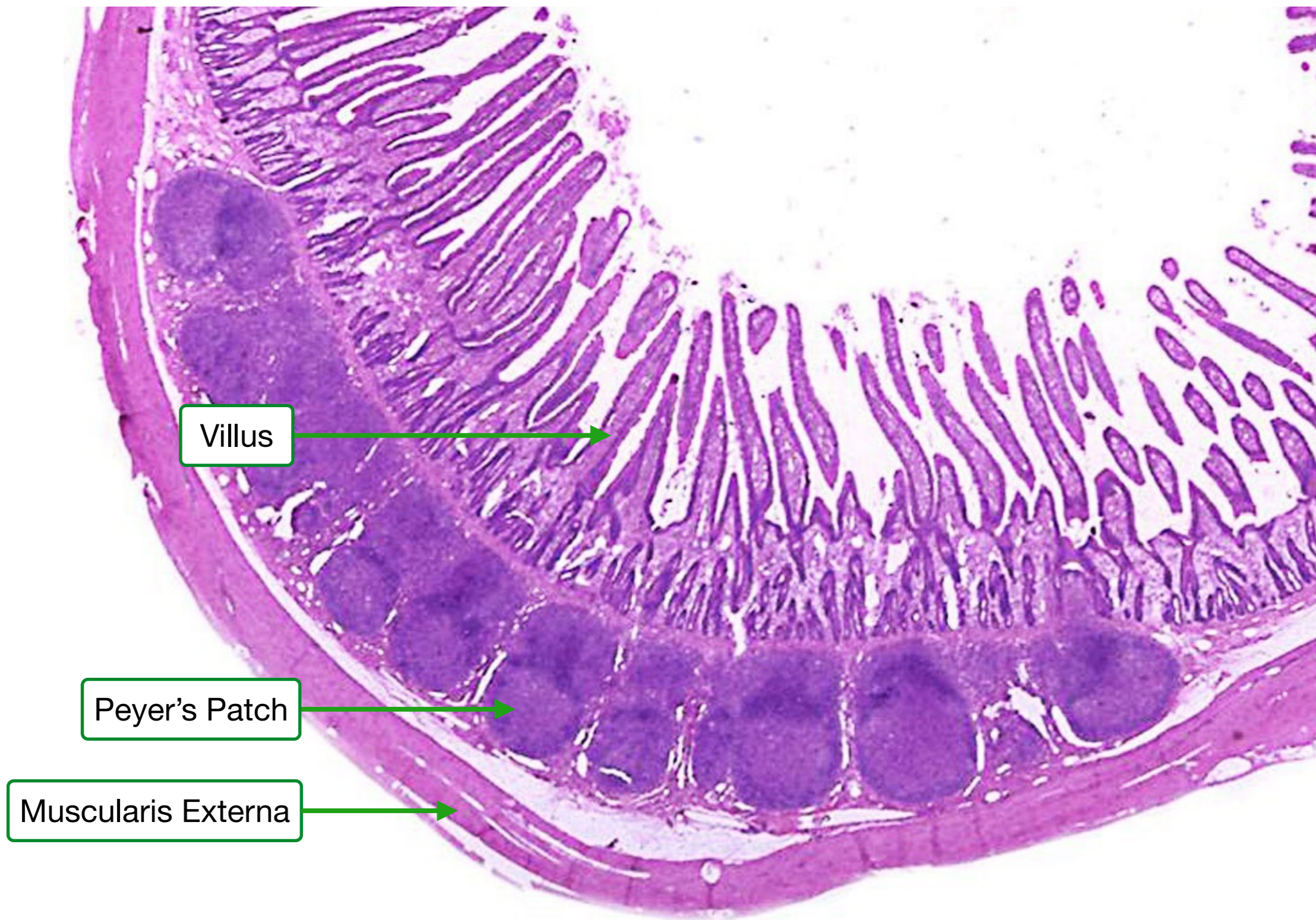


The jejunum has extensive plicae circulares to increase its surface area.

---

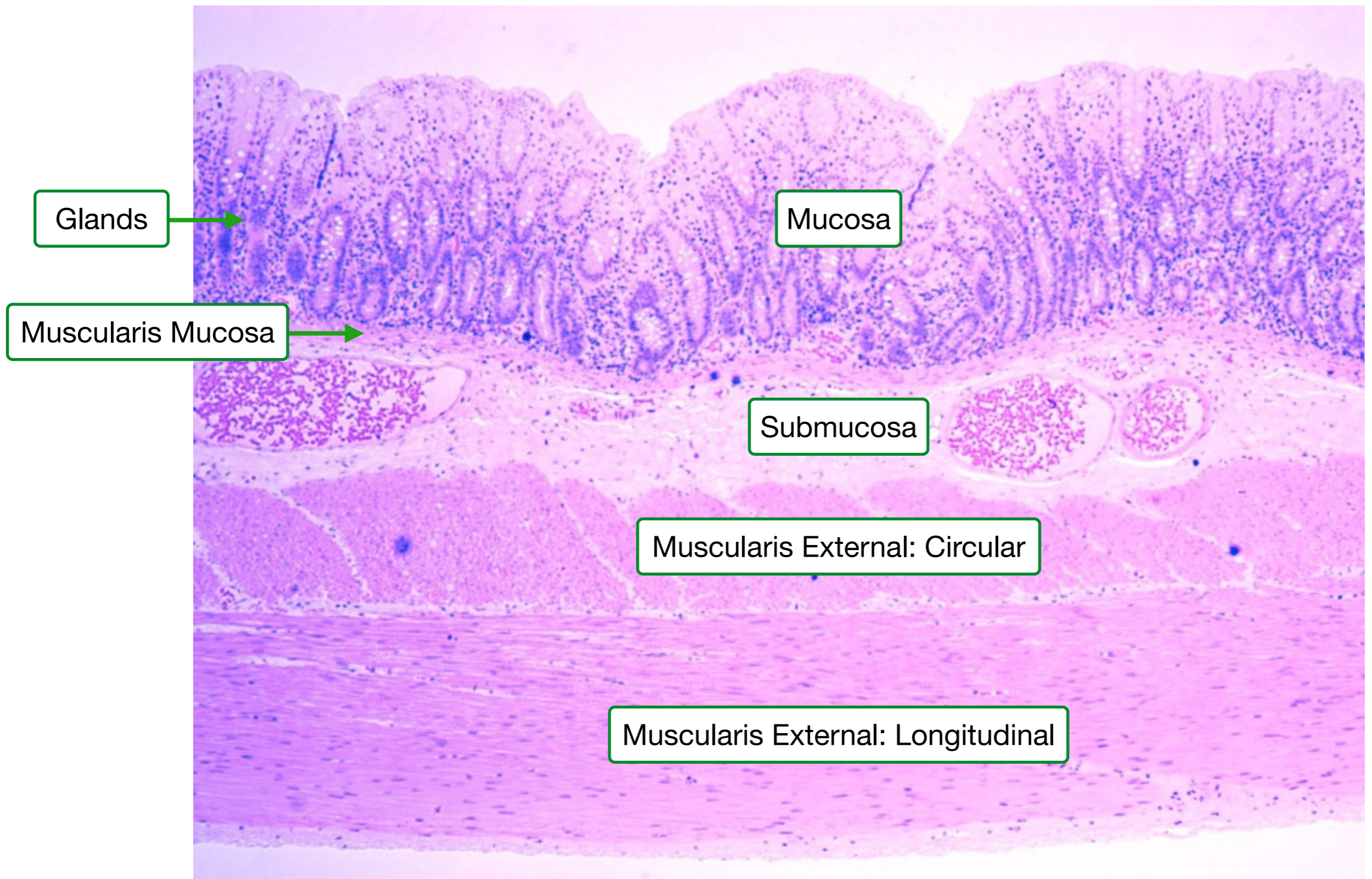


The ileum lack plicae circulares but contains Peyer's patches in its submucosa.

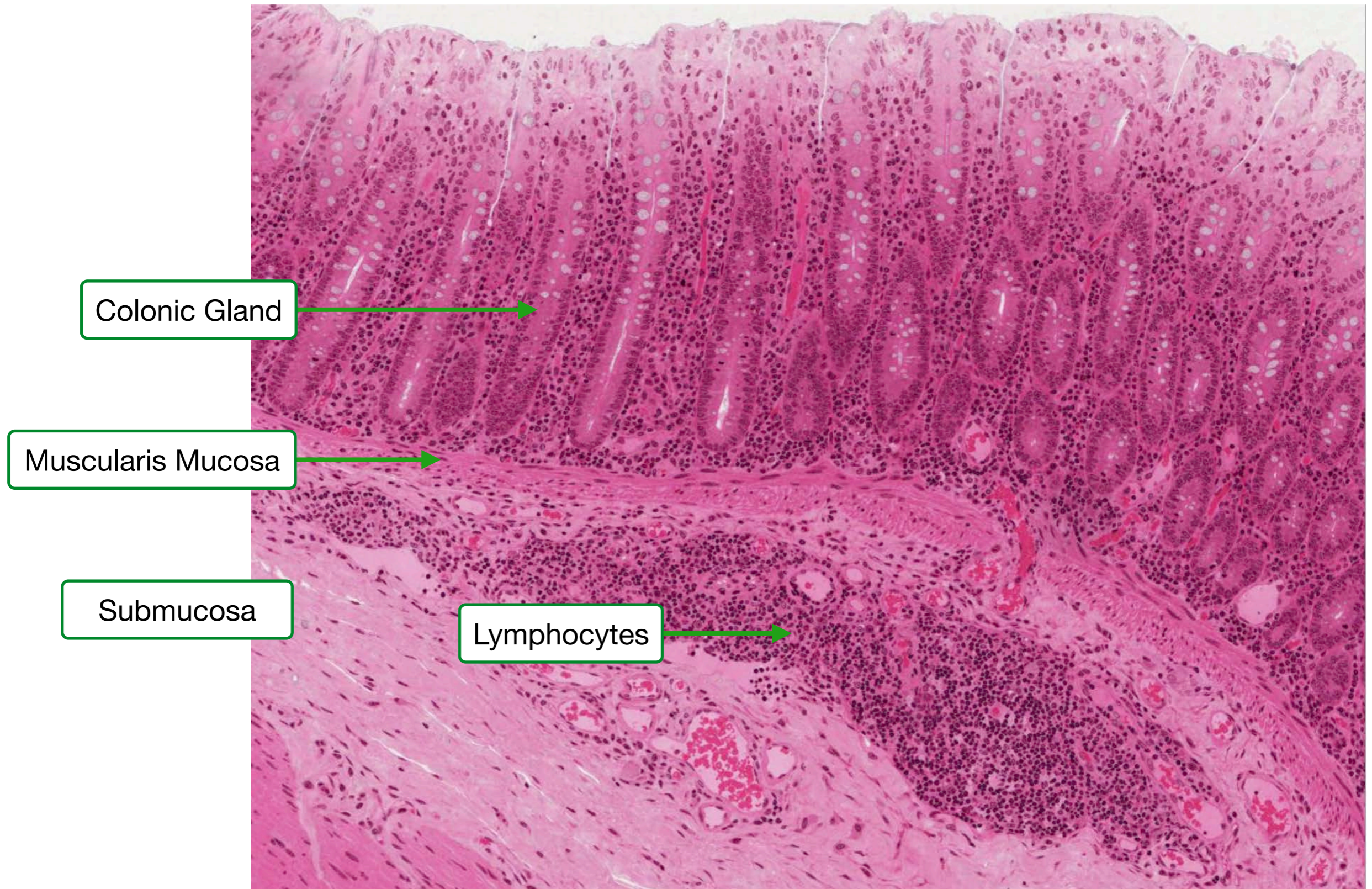


Large intestine

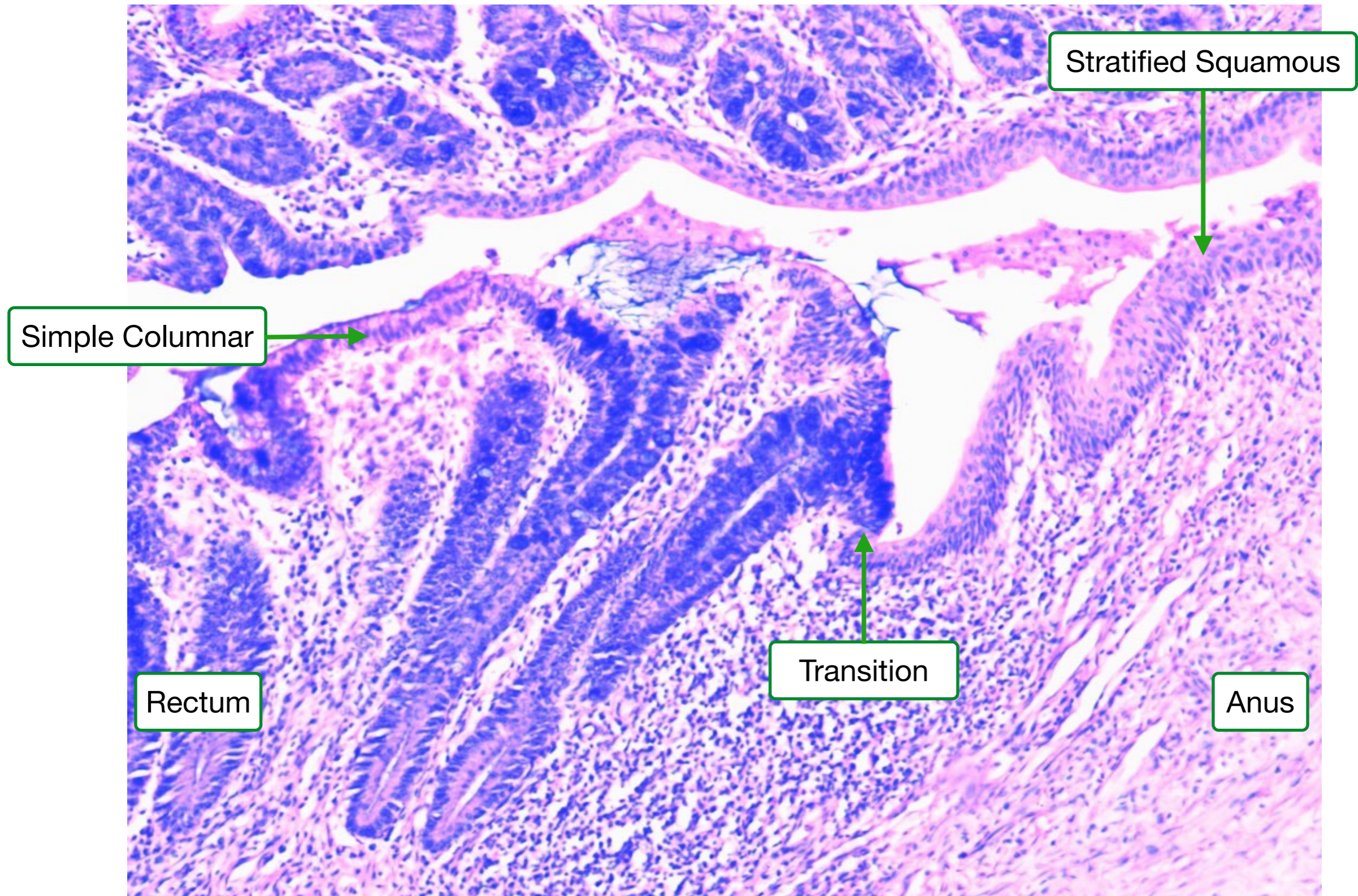
The colon concentrates waste and structurally lacks villi but contains glands.



The base of colonic glands contain stem cells and transit-amplifying cells and lymphocytes in the submucosa.



The epithelium transitions from simple columnar to stratified squamous at the junction between the rectum and anus.



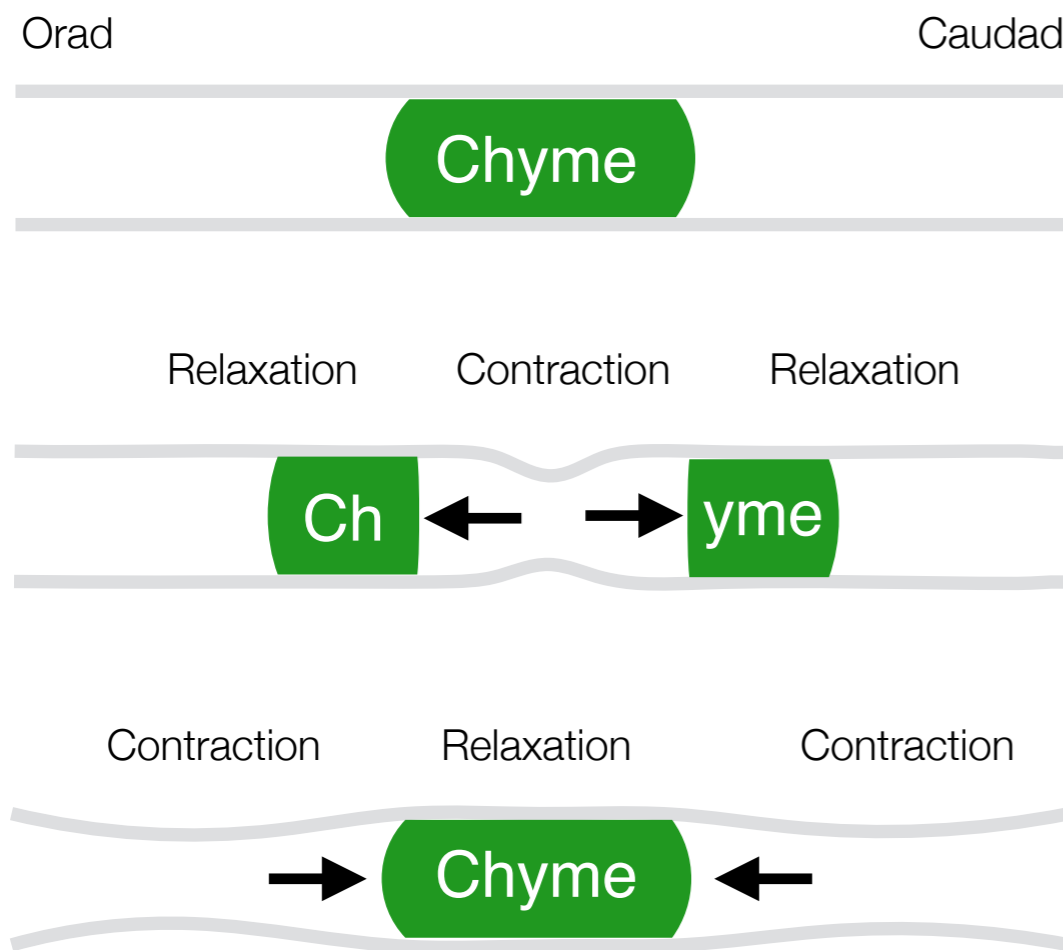


Mixing and propulsion of chyme

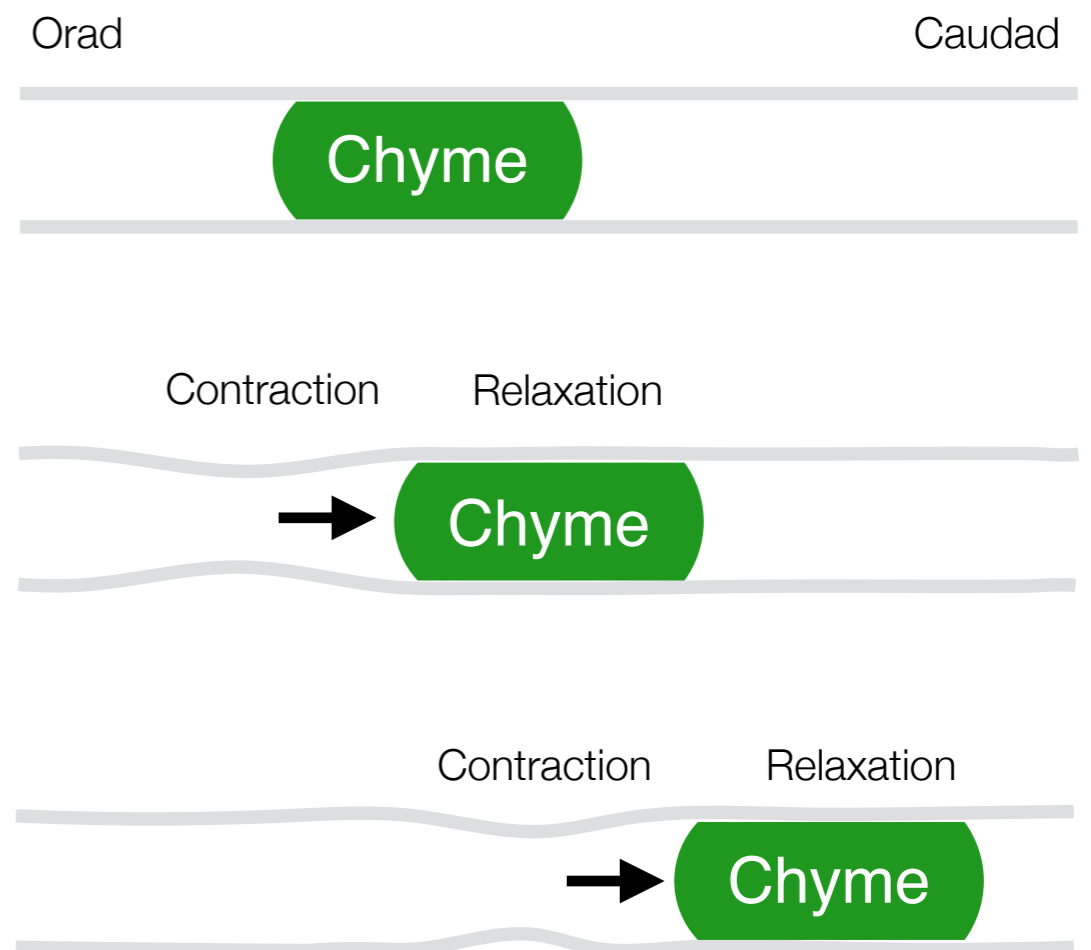
# Coordinated contraction of muscularis external layers mix and propel chyme.

---

## Segmented Contraction

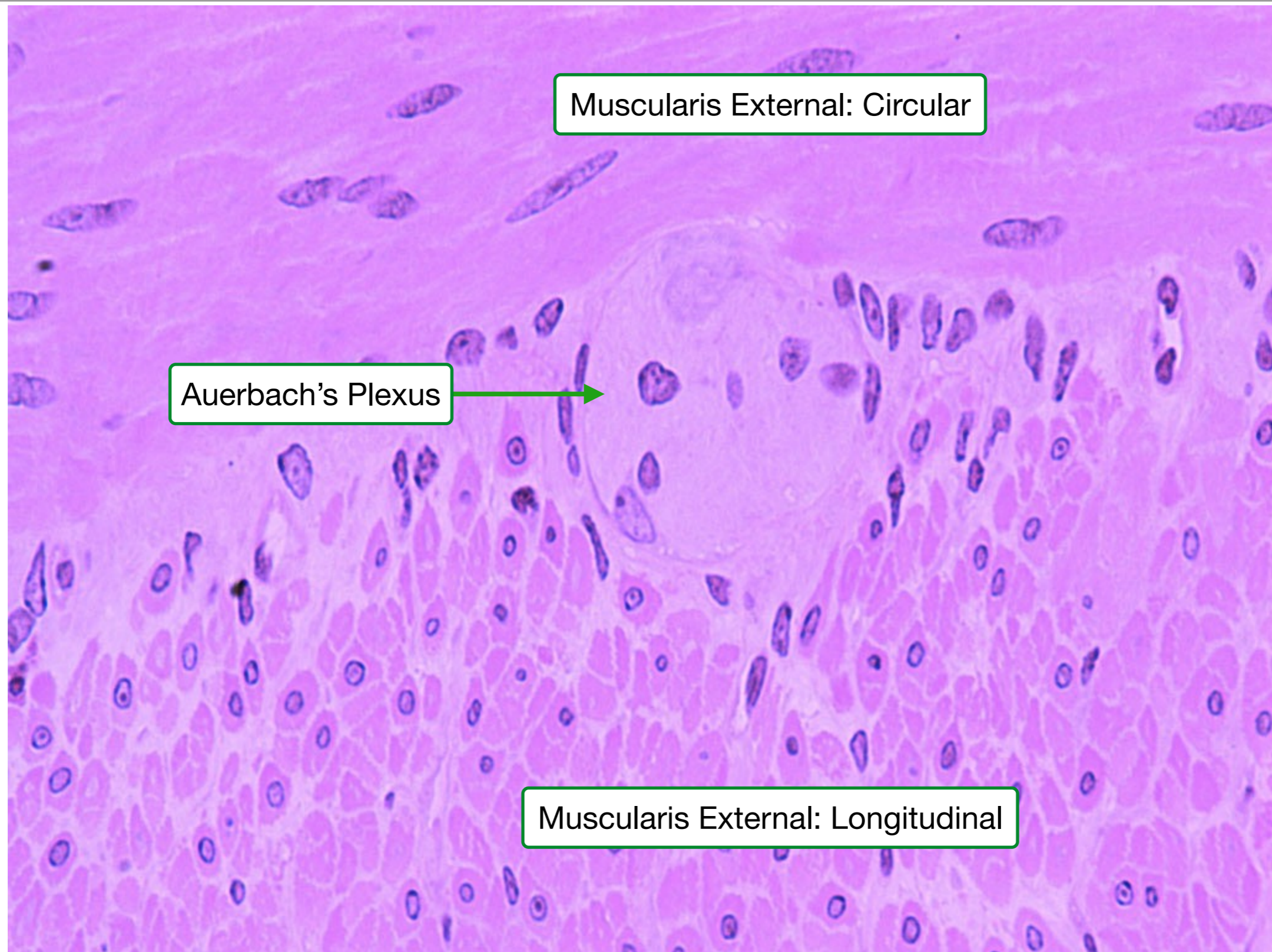


## Peristaltic Contraction



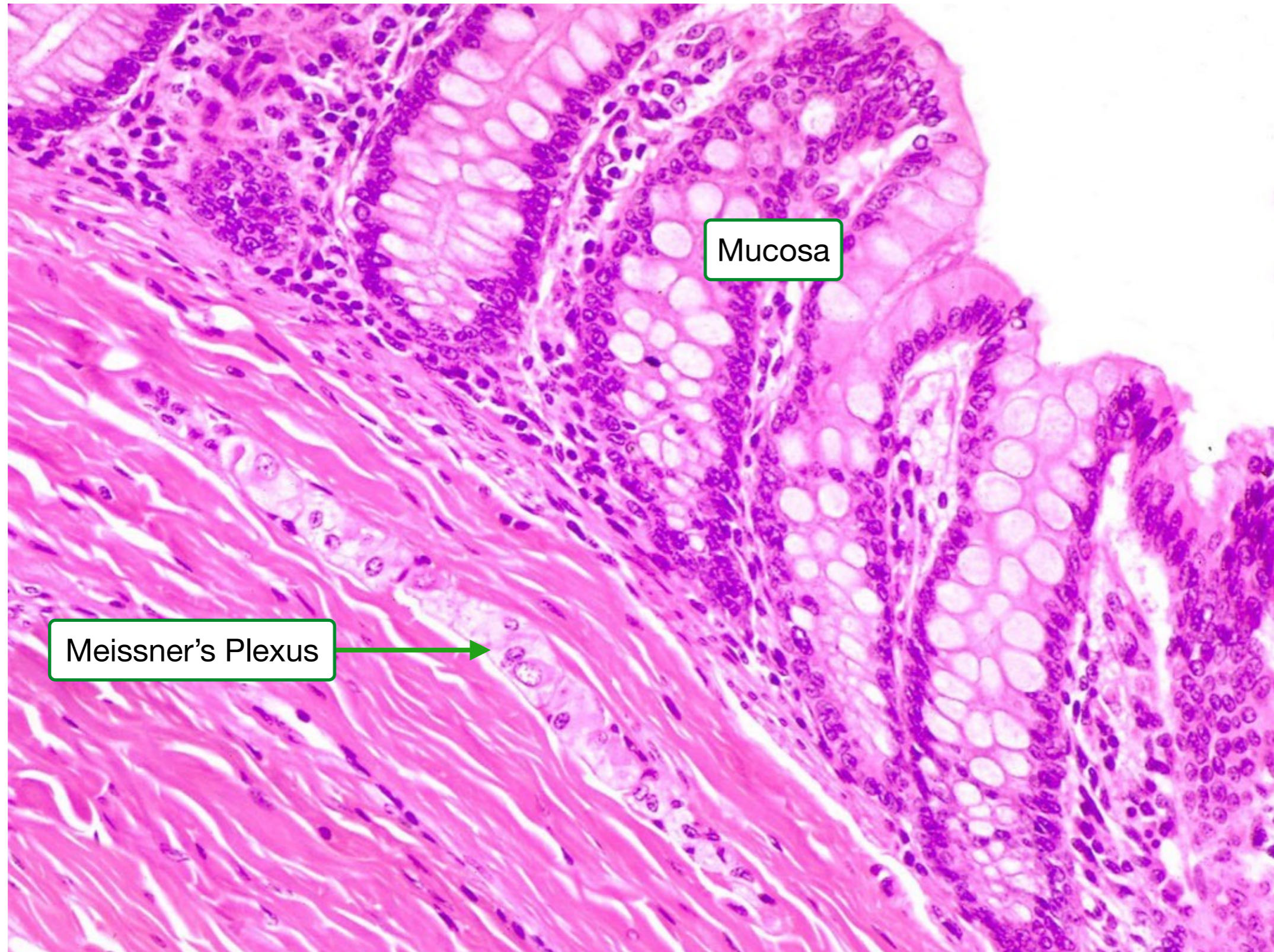Enervation

Auerbach's plexi are found between smooth muscle layers throughout the GI tract.



Meissner's plexi localize to the submucosa in the small and large intestine.

---



# Take home messages...

---

- The epithelium determines the primary functions of different segments of the GI tract.
- Acid production by parietal cells is regulated by several different molecules.
- The structure and secretions of gastric glands shows regional difference in the stomach.
- Microvilli, villi and plicae circulares increase the surface area in the small intestine.
- The base of villi in the small intestine and glands in the colon are the site of stem cells and renewal of the epithelium.